



DR. SAMUEL HAHNEMANN
GERMANY

NEUROLOGICAL DISORDERS

Vision of Impossible to Possible

**Treatment of
Incurable Diseases
Like Cancer, Kidney
Failure, Coma, Surgical,
Autoimmune, Life Style
& Life Threatening
Diseases**



PROF. DR. ARPIT CHOPRA JAIN

**M.D Homoeopathy
Critical and Surgical Disease Specialist (India)**

**INVENTOR OF
AAROGYA SUPER SPECIALITY MODERN HOMEOPATHY**

COMPLETE, EASY SAFE, FAST & COST-EFFECTIVE CURE



Dr. Arpit Chopra Jain M.D Homeopath

Critical and Surgical Disease Specialist

Dr. Arpit Chopra Jain: Transforming Global Healthcare with Aarogya super Speciality Modern Homeopathy.

Dr. Arpit Chopra Jain, a pioneer in advanced homeopathic medicine, is set to present groundbreaking clinical data comprising over 3,000 successfully treated cases of critical and surgical diseases — all cured without the need for surgery. This revolutionary treatment approach, developed and practiced exclusively by Dr. Jain, utilizes high-potency homeopathic medicines formulated by him, offering fast, safe, and side-effect-free results.

With over 21 years of experience, Dr. Jain has dedicated his life to providing an alternative yet powerful medical solution that not only preserves the body's original organs but also ensures deep, lasting cures. **His work has gained national and international recognition. He has been honored by India's Vice President, Defense Minister Shri Rajnath Singh, Health Minister Shri J. P. Nadda, and several other dignitaries.** In acknowledgment of his contributions, he has also received a prestigious honorary doctorate from the USA.

Dr. Arpit Chopra Jain proudly represents India on the international stage as the **Homeopathic Representative for BRICS (Russia)** and continues to raise the global profile of homeopathy through his one-of-a-kind center based in Indore, Madhya Pradesh, India. From this single center, he has reached and treated patients from over 19 countries, offering remote consultations and delivering life-changing results globally.

Recently, **Dr. Jain was invited as the Guest of Honor at the highly esteemed United Nations Global Excellence Awards held at the UN Headquarters in New York, hosted by the United Nations Global Peace Council.** This momentous occasion was a testimony to his relentless commitment and global vision for homeopathy.

His work is supported by real, verifiable patient testimonials, including pre- and post-treatment reports, available on his official website and YouTube channel. These authentic stories reflect the effectiveness and rapid healing power of his treatment.

This book is a humble attempt to introduce Dr. Jain's extraordinary journey and his mission — to make the world healthier without surgery, promoting natural healing through scientifically advanced homeopathic medicine. His goal is to create a safer, more cost-effective, and organ-preserving healthcare alternative for patients across the globe.





The identity of any person is his real wealth.

INTRODUCTION

Inventor of Aarogya Super Speciality Modern Homoeopathy, revolutionized treatment for complex diseases

Professor Dr. Arpit Chopra Jain

Professor Dr. **Arpit Chopra Jain**, with over 20 years of medical experience and research, has revolutionized classical homeopathy by developing a future-oriented, super-speciality modern homoeopathy treatment system. His innovative approach has given new physical, mental, and social life to thousands of patients who were once considered incurable, including those suffering from nearly 300 different diseases such as cancer, kidney failure, coma, aplastic anemia, and other serious conditions requiring surgical intervention. In doing so, he has also fulfilled the World Health Organizations (WHO) belief that true health encompasses physical, mental, and social well-being.

Originally from Chhattisgarh, Dr. Arpit Chopra Jain received his primary education in his home state before moving to Indore to pursue a Bachelors degree in Homeopathy. After completing his BHMS, he earned an MD in Homeopathy from DKMM Homoeopathic Medical College in Aurangabad, Maharashtra. During his studies and career, he worked alongside many renowned allopathic doctors in Indore and other locations, acquire practical experience and contributing to medical advancements.

Currently, Dr. Arpit Chopra Jain is providing medical services through the Aarogya Super Speciality Modern Homoeopathy Clinic, located at Janjirwala Square in Indore, where he leads a team of experienced professionals. In addition to his clinical work, Dr. Arpit Chopra Jain plays a pivotal role in shaping homeopathic education as an educator at RN Kapoor Homoeopathic Medical College. His research focuses on complex blood-related diseases, including aplastic anemia and sickle cell anemia.. Driven by a commitment to innovation, Dr. Jain has been nationally and internationally recognized for his groundbreaking contributions to the treatment of complex and incurable diseases. His exceptional service during the COVID-19 pandemic further highlights his dedication to advancing modern homeopathic medicine.

Many of Dr. Arpit Chopra Jain's patients regard him as a godsend, praising his unwavering commitment to serving humanity. Beyond his medical practice, Dr. Arpit Chopra Jain, who hails from a family of 19 physicians, is making significant contributions to society and the Nation.

He firmly believes that Aarogya Super Speciality Modern Homoeopathy - instant, effective, affordable, and without side effects is the future of homoeopathy. While homoeopathy may have originated in Germany, Dr. Arpit Chopra Jain is confident that India's revolutionary modern homoeopathic medical system will one day be recognized globally, inscribing India's name in golden letters on the world health chart. He and his team are making every possible effort to achieve this vision and will continue to do so.



Golden India's Revolutionary Discovery: Pioneering the Future of Healthcare with Advanced Homoeopathy

Homoeopathy, a system of alternative medicine established over 200 years ago by German physician Dr. Samuel Hahnemann, has experienced widespread adoption across various countries, including India. However, over time, it faced criticism and was even banned in certain regions due to persistent myths and misconceptions, such as its alleged placebo effect. Critics claimed that homoeopathic remedies were ineffective, slow to act, and not backed by scientific evidence, leading to widespread skepticism among both the public and the scientific community.

One significant issue was that classical homoeopathy relied heavily on treating patients based on symptoms alone, without extensive clinical documentation or diagnostic reports. This absence of empirical evidence made it challenging to validate its effectiveness through conventional medical research methods.

In response to these challenges, Dr. Hahnemann later developed a more potent form of homoeopathic medicine, known as the 50 millesimal potency, or 5 million power. However, by the time this advancement was introduced, classical homoeopathy had already established deep roots, and the lack of continued research, documentation, and clinical validation led to its gradual decline in some regions.

Recognizing the need to address these limitations, Professor Dr. Arpit Chopra Jain, with over 20 years of clinical and hospital experience, pioneered a groundbreaking approach known as Super Speciality Modern homoeopathy. Utilizing the powerful 50 lakh potency homoeopathic medicines, along with mother tinctures, biochemic treatments, and dilutions, Dr. Jain's revolutionized the practice by effectively treating severe autoimmune conditions, including cancer, kidney failure, aplastic anemia, sickle cell anemia, rheumatoid arthritis, ankylosing spondylitis, and many other life-threatening illnesses. This innovative treatment approach has produced remarkable results, enabling patients suffering from complex and incurable diseases to recover without any side effects or lifelong medication dependency. Dr. Jain's method has proven particularly effective in cases previously deemed untreatable, such as patients in comas, those with brain tumors, or those in the terminal stages of illness.



His success extends beyond India, benefitting patients in countries such as Pakistan, Dubai, Bangladesh, the United States, and the United Kingdom.

A key differentiator of Super Speciality Modern Homoeopathy is its integration of clinical pathology alongside traditional symptom-based diagnosis. Dr. Jain's has meticulously collected pre- and post-treatment test reports from over 3,000 successfully treated patients, along with their written testimonials and interviews, both online and offline. This substantial body of evidence aims to secure recognition for his treatment methodology within the broader medical community, ensuring future generations of homoeopathic practitioners can offer hope to patients who might otherwise remain hopeless.

Dr. Jain's innovative work continues to shape the future of homoeopathy providing a new path forward for both patients and healthcare providers worldwide.



Complete Cure, Permanent, Easy, Safe, Fast, Cost Effective.

Aarogya Super Specialty Modern Homoeopathy -

It is a modern medical science which incorporates the basic nature of homoeopathy and keeps it as its basis and includes many other new features.



Easy Method -

In Aarogya Super Speciality Modern Homoeopathy, a variety of homoeopathic medicines are utilized, including decimal potency, centesimal potency, 50 millesimal potency, mother tinctures, biochemic medicines, The method of administering these medicines is straightforward and can be easily followed in the prescribed dosage under the guidance of a qualified homoeopathic doctor. One of the unique aspects of Aarogya Super Speciality Modern Homoeopathy is that it does not work with the traditional restrictions often associated with homoeopathic treatment, such as avoiding strong-smelling substances during medication. Due to the high quality and potency of the medicines used, these minor misconceptions hold no relevance in this advanced system of treatment. This approach allows for effective treatment without the need for strict dietary restrictions, making it more accessible and easier for patients to adhere to. Aarogya Super Speciality Modern Homoeopathy excels in providing top-tier treatment with minimal medication, even for complex and difficult-to-treat conditions. In this system, various diseases are treated directly and comprehensively, whether through homoeopathic medicines alone or in combination with supportive medicines from other medical systems, depending on the patients condition and the nature of the disease. This holistic approach ensures that patients receive the most effective and personalized care

Harmless Medical Method -

One of the most remarkable aspects of Aarogya Super Speciality Modern Homoeopathy is its safety profile, even when high potencies are used. Unlike conventional treatments where the risk of side effects increases with the dosage of active ingredients, homoeopathic medicines are carefully prepared through a process called potentiation. In this process, the original substance is diluted while simultaneously increasing its potency. This unique method ensures that only a minimal amount of the chemical or raw material remains in the final product. As a result, Aarogya Super Speciality Modern Homoeopathy offers highly effective treatments without the risk of harmful side effects. The approach is practically unmatched in other branches of medical science, where larger doses of active substances can often lead to adverse reactions. In this way, modern homoeopathy provides a safe and natural healing method, making it an ideal option for individuals seeking a harmless yet potent solution to their health issues.

Fast Aggressive Treatment -

One of the most remarkable aspects of Aarogya Super Speciality Modern Homoeopathy is its fast and aggressive healing process, setting it apart from conventional homoeopathy. In this advanced system, medical expertise is combined with cutting-edge technology, including computerized software, to ensure rapid, accurate diagnosis and treatment. Doctors utilize a vast array of over 4,000 potent medicines, with strengths ranging from zero potency to an astonishing 50 lakh potency, making the treatment scientifically robust and effective for a wide range of diseases. The precision of this method allows doctors to quickly gather and analyze detailed information about a patients condition, helping them select the most suitable remedy. This tailored approach ensures that even severe, surgical, or seemingly incurable conditions are addressed efficiently and effectively. What makes this treatment truly revolutionary is its ability to provide fast relief without any side effects, transforming it into a powerful, unique, and highly reliable branch of medical science.

Complete cure of diseases from the root -

Aarogya Super Speciality Modern Homoeopathy aims to heal the patient completely body, mind, and soul ensuring not only recovery from current ailments but also preventing the recurrence of diseases throughout life. This holistic approach to treatment is a crucial aspect of any effective medical science.

This fast and aggressive treatment approach embodies the future of homoeopathy, offering hope to patients facing complex diseases while maintaining the core principles of safety, simplicity, and efficacy.

Cost-Effective Treatment with Aarogya Super Speciality Modern Homoeopathy

Despite its advanced and multifaceted approach, Aarogya Super Speciality Modern Homoeopathy remains highly affordable and accessible, making it a preferred choice for many. Compared to other medical systems, it offers a cost-effective solution while providing complete, safe, and test treatment. This affordability, combined with its ability to deliver immediate results without harmful side effects, has contributed to the growing global popularity of modern homoeopathy. Today, homoeopathy is trusted by millions, with affordable medicines available to those in need. Every fourth person in the world now benefits from homoeopathy in some form, relying on its holistic and comprehensive approach to healthcare.



Dr. Arpit Chopra Jain, M.D. in Homoeopathy and the inventor of Aarogya Super Speciality Modern - Homoeopathy, has been instrumental in making this revolutionary treatment accessible to people from all walks of life. His commitment to providing effective, affordable, and harmless treatment has redefined the landscape of healthcare, offering hope and healing to thousands.



Dr. Arpit Chopra (Jain)
 M.D. HOMOEOPATHY
 Inventor of Aarogya Super Speciality Modern Homoeopathy



Aarogya Super Speciality Modern Homoeopathy



Successful Treatment of Critical Health Conditions

Dr. Jain's innovative treatment method has shown exceptional results in managing and curing serious health conditions, including:

- Cancer
- Kidney Diseases
- Coma
- Blood Disorders such as sickle cell anemia and aplastic anemia
- Arthritis
- Autoimmune Diseases
- Neurological Disorders
- Heart Diseases
- Skin Conditions like psoriasis and dermatitis

Through a deep understanding of the body's internal balance, Aarogya Super Speciality Modern Homoeopathy targets the root causes of these diseases, promoting natural self-healing without the need for invasive procedures or lifelong medications.

Revolutionizing Disease Treatment

Aarogya Super Speciality Modern Homoeopathy, developed by Dr. Arpit Chopra Jain, has introduced a groundbreaking, holistic approach to treating a wide range of complex and chronic diseases. This method offers a comprehensive, harmless, cost-effective, and permanent solution, achieving remarkable success where conventional treatments often fall short.

Efficacy Across a Wide Range of Diseases

With a proven record of success in treating nearly 300 different diseases, Aarogya Super Speciality Modern Homoeopathy offers relief from conditions that affect various aspects of health. Patients suffering from:

- Allergies
- Womens Health Issues
- Urological and Gastric Problems
- Rheumatoid Arthritis
- Pediatric Conditions
- Spinal Cord Disorders

have all experienced life-changing results through this pioneering method.



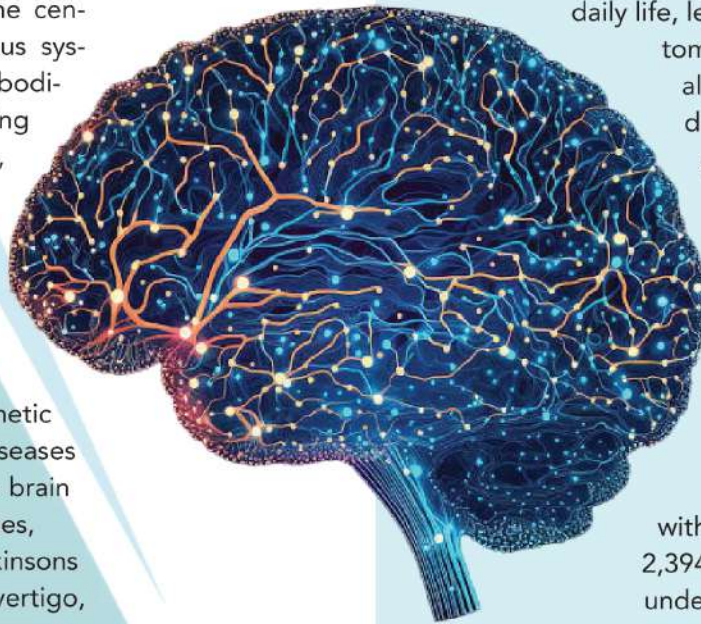
A New Lease on Life

What truly sets this treatment apart is its ability to provide lasting and permanent relief. Patients who were previously dependent on lifelong medication or faced invasive surgeries have regained their health, returning to a normal, medication-free life. Aarogya Super Speciality Modern Homoeopathy continues to transform lives, offering a new, holistic approach for those suffering from complex and chronic diseases.

Neurological Disorders

The Brain: Central to Our Well-being and the Challenge of Neurological Disorders

The brain serves as the central hub of our nervous system, orchestrating all bodily functions, processing sensory information, directing motor activities, and maintaining cognitive and emotional balance. When neurological disorders disrupt brain function whether from genetic causes, accidents, or diseases serious conditions like brain strokes, haemorrhages, tumors, epilepsy, Parkinsons disease, migraines, vertigo, and paralysis can arise.



The Impact of Neurological Disorders

These conditions can profoundly impact daily life, leading to debilitating symptoms or even coma. Traditional allopathic medicine often addresses these issues with surgery or lifelong medication. However, such treatments may offer only partial relief and can contribute to ongoing frustration and a sense of hopelessness. In India, approximately 30 million people are affected by neurological disabilities, with a prevalence rate of about 2,394 cases per 100,000 people, underscoring a significant public health challenge.

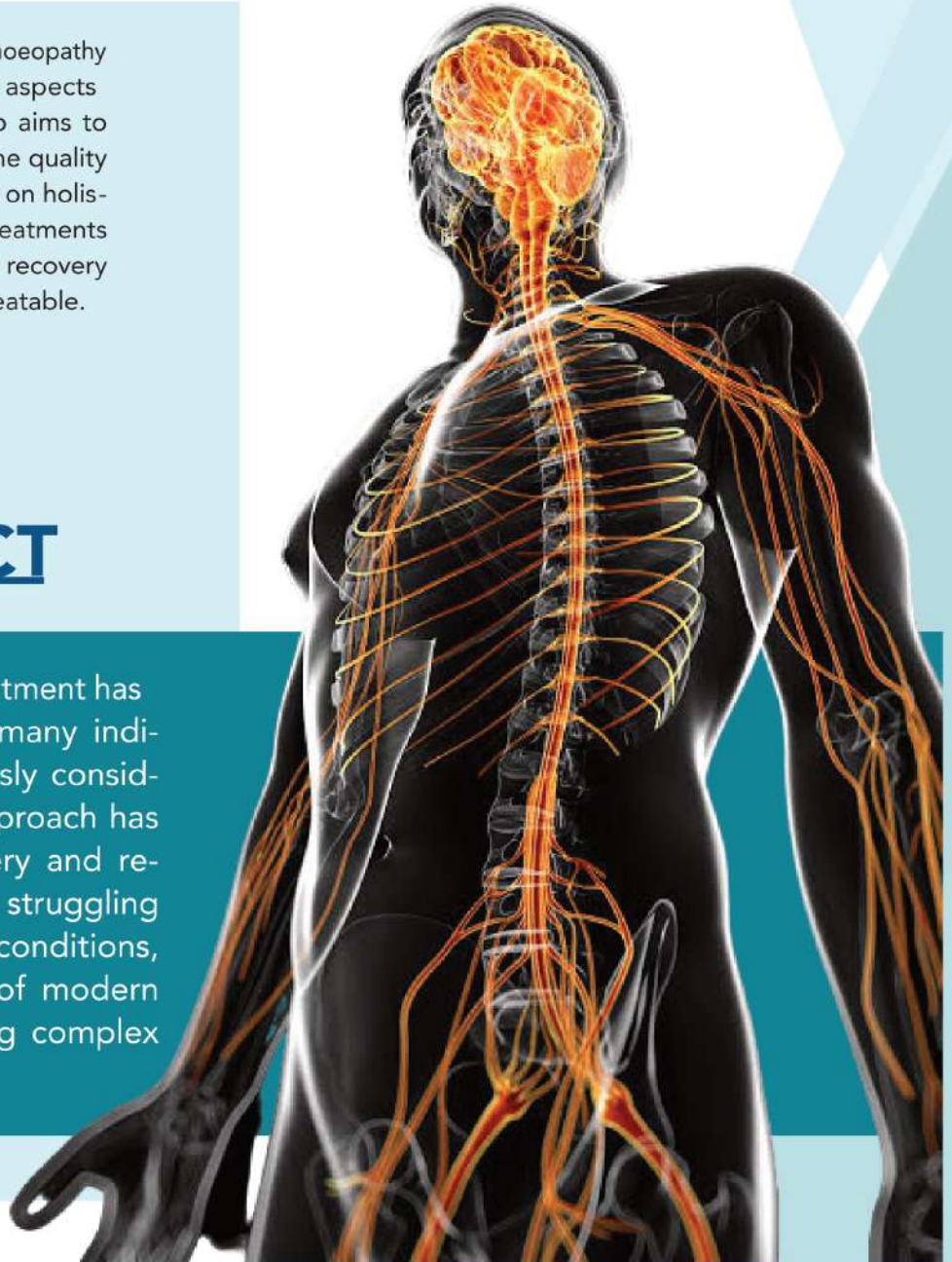A New Hope with Modern Homoeopathy

Dr. Arpit Chopra Jain offers a promising alternative through his Aarogya Super Speciality Modern Homoeopathy. With over 20 years of extensive research and medical experience, Dr. Arpit Chopra Jain has developed innovative treatments for severe neurological conditions. His approach has shown remarkable success in treating conditions such as coma, brain tumors, and brain cancer, providing relief where traditional methods have struggled.

Dr. Arpit Chopra Jain's modern homoeopathy not only addresses the physical aspects of neurological disorders but also aims to restore confidence and improve the quality of life for his patients. By focusing on holistic and individualized care, his treatments offer renewed hope and effective recovery for those previously deemed untreatable.

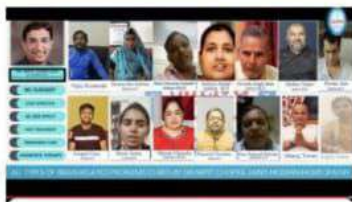

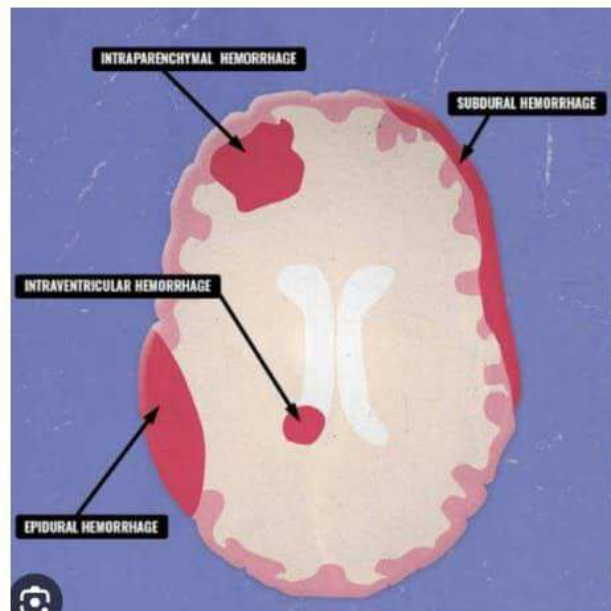
SUCCESS STORIES AND IMPACT

Dr. Arpit Chopra Jain's treatment has transformed the lives of many individuals who were previously considered beyond help. His approach has provided effective recovery and renewed hope for patients struggling with severe neurological conditions, illustrating the potential of modern homeopathy in addressing complex health challenges.



Conclusion

Neurological disorders represent a significant challenge due to their complex nature and the profound impact they can have on daily life. Traditional treatments often offer limited relief, but Dr. Arpit Chopra Jain's Arogya Super Speciality Modern Homoeopathy provides a hopeful alternative. Through his innovative methods, patients suffering from severe neurological conditions can find effective treatment and regain their quality of life, moving beyond the limitations of conventional medicine.




Description

NEUROLOGICAL BRAIN DISEASES
 न्यूरोलॉजिकल बीमारी MANY TYPES
 CURED BY DR ARPIT CHORA
 MODERN HOMEOAPTHY



असंभव को संभव



NEUROLOGICAL BRAIN DISEASES
 न्यूरोलॉजिकल बीमारी MANY TYPES
 CURED BY DR ARPIT CHORA
 MODERN HOMEOAPTHY

पक्षाघात या लकवा मारना
 Paralysis of 13 years ...

Types of Paralysis

Intraventricular haemorrhage (IVH) is defined as the eruption of blood in the cerebroventricular system and occurs mostly secondary to intracerebral haemorrhage (ICH) in adults. Hydrocephalus is a severe complication of IVH that can serve as an independent predictor of increased mortality.

AGRAWAL DIAGNOSTIC CENTRE
JAIN • INDORE

MR (3 Tels)
C.T. Scan (18 Slic)
3D/4D Sonography
Colour Doppler
DPL - CA & CB
Fetal MRI (1.5 & 3.0)
JMS & RPT
Diploma Neurophysiology
Schizophrenia
EPILEPSY

After Dr Arpit Chopra Jain Modern Homoeopathy

Patient ID: 1012345
Age: 50 Years
Accession Number: 1012345
Referring Physician: DR. ARVIND GUPTA
Date: 01-Sep-2023

Parent Name: SUNIL KUMAR SINGH
Sex: M
Maiden: CT
DOB: 1973

NCCT HEAD

Multiple small focal hypodense areas are seen in bilateral periventricular regions, basal ganglia and thalamus, likely representing chronic lacunar infarcts. Bilateral small focal areas of possible chronic lacunar infarcts are also seen in brainstem.

Remaining overall brain morphology in supratentorial compartment appears normal. No other focal lesion.

There is no fresh hypodense intracranial hemorrhage. There is no abnormal extra-axial collection or herniation. There is no midline shift or brain herniation.

Sella and bilateral parasellar regions appear normal. Grains and cerebellum otherwise appear grossly normal. Ventricles are intact. No hydrocephalus.

Bones of skull and visualized facial skeleton appear unremarkable. Bilateral orbits and temporal bones appear grossly unremarkable.

Dr. Arpit Chopra Jain's YouTube channel content:

- Central Atrophy with Epilepsy...
- Epilepsy Cured by Dr. Arpit C...
- Central Atrophy with Epilepsy...
- Dr. Arpit Chopra Jain

न्यूरोलॉजिकल बीमारी
NEUROLOGICAL BRAIN DISEASES Cured

एपिलेप्सी के लिए चीन उपचारिक उपचार

Cerebral Atrophy is a common feature of many of the diseases that affect the brain.

Cerebral atrophy—the loss of nerve cells (neurons) and the connections that help them communicate in the brain's tissues—occurs in many disorders that affect the brain, such as

KNOW ABOUT CEREBRAL ATROPHY (BRAIN ATROPHY)

Loss of coordination
Partial paralysis
Double vision
Memory loss
Difficulty with communication
Loss of reasoning ability
Onset of learning disabilities

DR. PANJABRAO ALIAS BHUSAHEB DESHMUKH MEMORIAL MEDICAL COLLEGE & HOSPITAL, AMRAVATI.

Patient Name: SISANGIYA PRIYANSHI
Age: 3 Years
Referred by: Dr. R. Thakre Sir
Examination: BRAIN
Date: 15-Mar-2023

MRI BRAIN

IMAGING PROTOCOL: Axial TSE T2 WI, Axial FLAIR T1 and T2 WI, Coronal Fat Sat T2WI, Sagittal SE T1WI, Axial Diffusion WI.

MR SHOWS:

- Mild brain atrophy is seen.
- Thinning of posterior part of body of corpus callosum.
- Rest of both the cerebral hemispheres are normal in signal intensity.
- Both the lateral ventricles are normal.
- Third ventricle is normal and in midline.
- Both basal ganglia & thalami and both internal capsules are normal in signal intensity.
- Midbrain, pons & medulla appear normal.
- Cerebellum & fourth ventricle are normal.
- Both hippocampal and amygdala appear normal in signal intensity.
- Anterior and posterior pituitary gland appears normal.
- Hypothalamic area is normal.
- No evidence of any mass in pituitary or hypothalamus.

IMPRESSION: MRI brain shows mild brain atrophy.

Before Treatment

Dr. Arpit Chopra Jain
Senior Resident

Dr. Sandhya Rothari
Prof. ARIID

Dr. Priyanshu Deshmukh
Senior Resident

Dr. Sandhya Rothari
Prof. ARIID

Dr. Ravi S. Bang
M.B.B.S. D.M.R.D.
DIP. in Musculoskeletal
Ultrasound Mus-Ucam University (Spain)
Fellowship in Fetal Scholar MD
Special training in gynaecology and infertility imaging.

care Diagnostic Center

| | | | |
|------------------|---------------------------|------------|------------|
| NAME OF PATIENT: | Mast. Priyansh Sinsangiya | AGE / SEX: | 3 YRS / M |
| REFERRED BY: | Dr. R. Thakre Sir | DATE: | 27.02.2024 |
| REGD NO: | M47022024 | | |
| EXAMINATION: | MRI BRAIN | | |

TECHNIQUE: MRI of brain was performed using T1, T2 weighted & FLAIR sequences in multiple planes.

OBSERVATION:

The study reveals thinning of the isthmic part of corpus callosum measuring up to 2.0 mm - suggestive of corpus callosal dysgenesis.

Genu of corpus callosum measures up to 7.3 mm.
Ventral part of body of corpus callosum measures up to 7.0 mm.

There is normal signal intensity pattern of cerebral parenchyma, with no obvious focal lesion. No evidence of intra or extra-parenchymal hemorrhage.

Both striato-capsular regions & thalami show normal morphology and signal intensity. Sella & supra-sellar region appear normal.

Ventricular system is normal in size, shape & position. No midline shift. Subarachnoid spaces and basal cisterns appear normal.

Cerebellum and brainstem show normal morphology and signal intensity. Both ponto-cerebellar angles appear normal. Membranous labyrinth on either side show normal signal intensity.

Visualized bilateral internal carotid arteries & basilar artery show normal flow void.

IMPRESSION:

MRI study of brain reveals thinning of the isthmic part of corpus callosum suggestive of corpus callosal dysgenesis.


after Dr Arpit Chopra Jain Modern Homoeopathy

Dr. Ravi S. Bang
M.B.B.S. D.M.R.D.
DIP. in Musculoskeletal
Fellow in Fetal Scholar MD
Special training in gynaecology and infertility imaging.

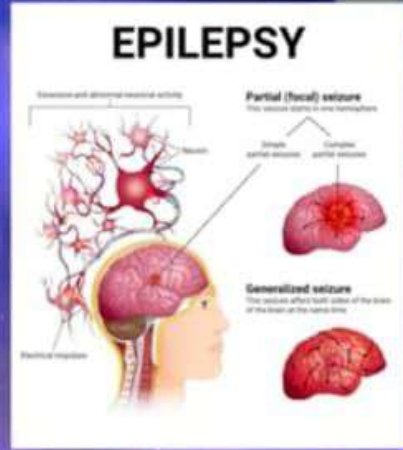
Disclaimer: The science of radiological diagnosis is based on the interpretation of various studies produced by both the normal and abnormal tissues and is neither complete nor accurate. Further pathological and radiological investigations with direct correlations are required to enable the doctor to reach the final diagnosis. In case of any clinical/radiological discrepancy, please contact.



आरोग्य सुपर स्पेशलिटी मॉडर्न होम्योपैथिक क्लिनिक



Mr. Ishwar Singh
Epilepsy Patient From Rajasthan



0731-4977076
+91 9907527914
+91 7828318923
+91 97130-92737
+91 97130-37737
+91 79999-78894

जब होम्योपैथी से इलाज़ संभव है तो ऑपरेशन में जल्दबाजी क्यों ?

Emergency No. +91 9340495872

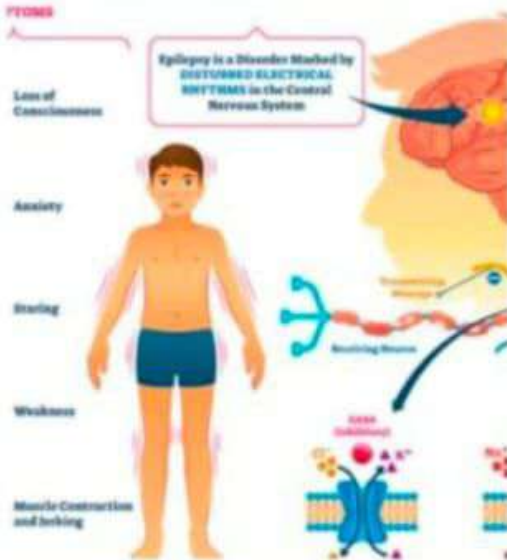


Dr. Arpit Chopra, MD

www.homoeopathy.cure.in, www.aarogyahomoeopathyindore.com / www.besthomoeopathydoctorind.com Email:- arpitchopra23@gmail.com

EPILEPSY

Epilepsy is a Disorder Marked by DISTURBED ELECTRICAL RHYTHMS in the Central Nervous System



Calcified Granuloma & Brain Tumour cancerous & non cancerous cured & responded by Dr Arpit... Read more

clo Epilepsy: 2009
- on Rx
- Last episode - Oct 2022
- Last for - 5-7 mois
- Vertigo ⊕
- Nausea

After Dr Arpit Chopra Jain Modern Homoeopathy

March 2016

Writer's Cramp

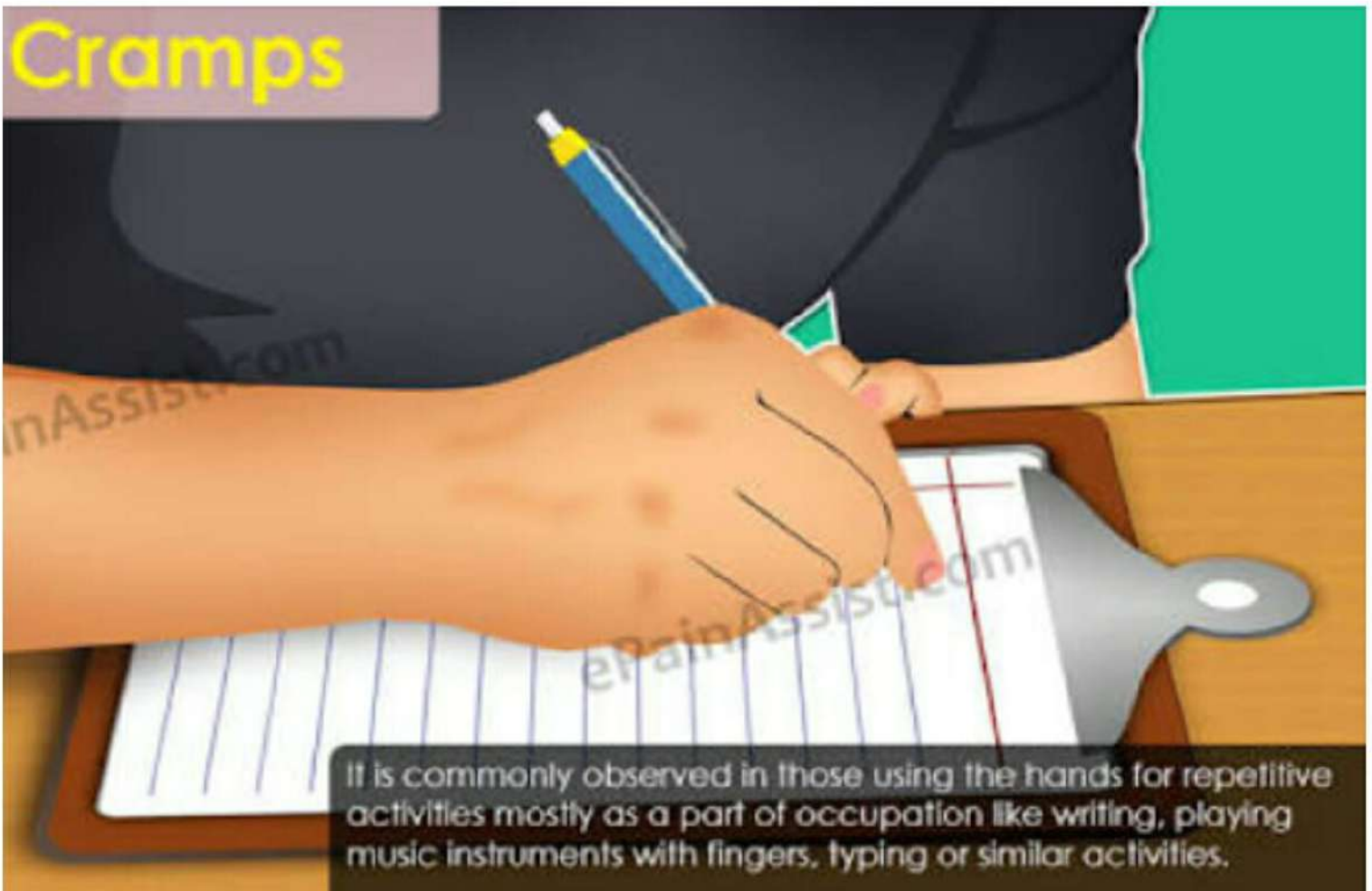
👁 Essential ♦ Follow-up

Saturday

med - 94 259 11191

19 Pooja Jain → To good in treatment. My son have shivering in his hand it seemove within 15 days. with this medicons.

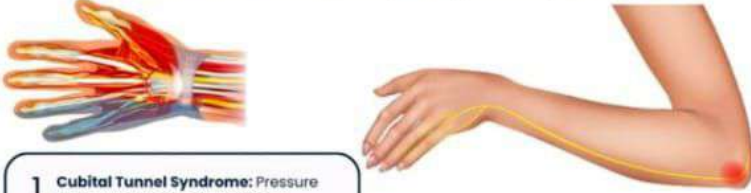Cramps



It is commonly observed in those using the hands for repetitive activities mostly as a part of occupation like writing, playing music instruments with fingers, typing or similar activities.

Common Causes of Ulnar Neuropathy

Early diagnosis and targeted treatment for ulnar neuropathy can make a world of difference. But it all starts with uncovering the culprit behind your nerve pain.



- 1 Cubital Tunnel Syndrome:** Pressure on the ulnar nerve at the elbow.
- 2 Guyon's Canal Syndrome:** Compression at the wrist.
- 3 Injury or Trauma:** Fractures, dislocations, or direct blows to the elbow or wrist.
- 4 Repetitive Movements:** Leaning on elbows, using certain tools, or activities with repeated bending.
- 5 Anatomical Variations:** Some people are naturally prone to nerve compression due to slight bone or tissue differences.
- 6 Underlying Conditions:** Diabetes, tumors, or arthritis can affect the nerve or surrounding structures.
- 7 Inflammatory Disorders:** Arthritis or other inflammatory conditions can put pressure on the nerve.

AAROGYA SUPER SPECIALITY MODERN HOMOEOPATHIC CLINIC

DR ARPIT CHOPRA JAIN
(MD HOMOEOPATHY CRITICAL & SURGICAL DISEASE SPECIALIST)

RESPONDED NERVE COMPRESSION PATIENT FROM INDORE, MADHYA PRADESH

Disease to Save Lifetime Drug Dependency, Treatment of 300 Types of Incurable Complex Diseases.

Responded Ulnar Nerve Compression Patient Treated by Dr. Arpit Chopra Jain..

65 views 2d ago ...more

SYMPTOMS

WEAKNESS
DECREASED GRIP STRENGTH
TENDON SPASMS
WEIGHT LOSS
REDNESS, PAIN, and TINGLING (PARESTHESIA) in HAND

↓

WASTING of the FOURTH and FIFTH FINGERS
PERMANENT DISABILITY

PATHOPHYSIOLOGY

COMPRESSIVE NEUROPATHY ANYWHERE ALONG LENGTH of ULNAR NERVE

CAUSES

- * ULNAR NERVE ENTRAPMENT at the ELBOW**
 - CUBITAL TUNNEL SYNDROME
 - ELBOW INJURIES
 - BONE and JOINT DISEASE
 - REPEATED BENDING
 - EXCESSIVE LEANING
 - DIABETES
 - HEREDITARY NEUROPATHY with PRESSOR PALSIES (HNPP)
- * ULNAR NERVE ENTRAPMENT at the WRIST**
 - DIRECT TRAUMA
 - LACERATION
 - GANGLION CYSTS
 - ULNAR TUNNEL SYNDROME
 - DISTAL VASCULAR ANOMALIES
 - SOME JOINT CONDITIONS
 - CHRONIC and REPEATED EXTERNAL PRESSURE

Ulnar neuropathy at the elbow

Overview

Ulnar neuropathy at the elbow, also known as cubital tunnel syndrome, occurs when the ulnar nerve is compressed, stretched, or irritated as it passes behind the elbow. Symptoms include numbness, tingling, and weakness in the hand and fingers.

Prevention

Ulnar neuropathy at the elbow, also known as cubital...

Causes

Ulnar neuropathy at the elbow can have several causes,...

Aarogya Superspeciality Modern Homoeopathic Clinic

Dr. Arpit Chopra (Jain)

- Cancer Disease
- Kidney Disease
- Chronic and hospitalized patient
- Surgery and Operation (Surgical Disease)
- Autoimmune Disease
- Rheumatology Disease
- Life Long Drug Dependent Disease
- Surgical Disease
- Eye Disease
- Allergy Disease
- Gastro Disease
- Cardiac Disease
- Urology Disease
- Hepatic Disease
- Neurology and Intensity Disease
- Neurology Disease
- Ophthalmology Disease
- Vascular Disease
- Hematology Disease
- Pulmonary Disease
- Orthopedic Disease
- Dermatology
- Acute Disease
- Neuroendocrinology Disease
- Flu
- Pediatric Diseases
- Gen and Genetic Disease
- ENT (Ear, Nose, Throat) Disease
- Endocrine and Hormone Disorder

Dr. Arpit Chopra (Jain)

MD Homoeopathy, Critical Surgical Disease Specialist

Dr. Arpit Chopra (Jain)

MD Homoeopathy, Critical Surgical Disease Specialist

A.S.S.M.H

(Aarogya Super Speciality Modern Homoeopathy)

Dr. Arpit Chopra (Jain) is a highly qualified and experienced Homoeopathic Doctor. He has completed his MD in Homoeopathy from the University of Delhi, India. He has been practicing Homoeopathy for over 20 years. He has treated thousands of patients with various chronic and acute diseases. He is known for his expertise in treating complex and incurable diseases. He has a vast knowledge of Homoeopathic remedies and their application. He is a member of the Indian Homoeopathic Association and the World Federation of Homoeopathic Societies. He is also a frequent speaker at various conferences and seminars. He is committed to providing the best possible care to his patients. He is available for consultations in person and online. He can be reached at +91 98112 34567. His clinic is located at Aarogya Super Speciality Modern Homoeopathy, Indore, Madhya Pradesh, India.

Scan QR For More Information

SKS NEUR
POLYTRAUMA HOSPITAL
STATION ROAD, KACHIGUDA, HYDERABAD - 500 027.
PHONE : 040-4477 2899, 2755 1314 | FAX : 040-66615888
WWW.SKSHOSPITAL.COM

Req Nos : 140472 Ip No. :
Patient Name : ARPITA Req Date : 16/01/2017 11
Age/Gender : 19 Years Female Sample Date : 16/01/2017
Con. Dr : DR.GOVARDHAN REDDY P
Ref. Dr : null Reporting Date : 16/01/2017 11

MRI SCAN OF BRAIN WITH EPILEPSY PROTOCOL

TECHNIC :
T1 Axial, T1 Sagittal, T1 Coronal.
Flair Axial, T2 Axial, DWI.
T2 Relaxation coronal, T1 Tirm coronal, T2 flair coronal.

RESULT :

- Atrophy of the hippo campal region on left side.
- Ventricular system appear normal.
- Sulci and sub arachnoid spaces appear normal.
- Normal signal morphology of the brain plain on T1 and T2 WI.
- Normal gray and white matter differentiation.
- No evidence of haemorrhagic pathology.
- No evidence of space occupying lesion.
- Sella and para sellar regions appear normal.

IMPRESSION :

- Normal brain signal morphology.
- Atrophy of the hippo campal region on left side.

For Clinical Correlation.

DR. V. CHALAPATHI RAO
RADIOLOGIST.

* Partial Reproduction of this report is not permitted*

24 HOURS SERVICE
MRI 1.5 Tesla, Spiral C.T. Scan, 2D Echo, Endoscopy, Doppler Study, ECG, EEG, &
Video ES - 32 Channels, T.M.T. Ultra Sonography, 500 MA Digital X-Ray, Exhaustive Lab Investiga
NABL ACCREDITED LAB (BIOCHEMISTRY)

SODANI DIAGNOSTIC
HO. : L.G-1, Morya Centre, Opp. Basket Ball Club, 16/1, Race Course Road, Indore

Patient's Name : Ms. Arpita Chopra Visit Id : 101802
Age / Sex : 19 Years / FEMALE Reported : 12/04/2018
Referred By : Dr.Chopra Arpit Company : NA

MRI Brain

Technique :
Routine sequences were acquired in multiple planes, to evaluate the brain.

Imaging Findings :-
The brain parenchyma and ventricular systems appear normal.
No focal structural lesion has been identified.
No acute lesion or restricted diffusion is seen.
No haemorrhage, edema, mass effect or midline shift is seen.
Brain stem & cerebellum appear normal.
The sella, parasellar structure & CVJ appear normal.
Visualized paranasal sinuses and mastoid air cells appear unremarkable

Remarks:
No significant abnormality detected on this study of the brain. No acute I

DR. BHARAT JAIN
M.D. [Radio-Diagnosis]
Fellowship in Diagnostic Neuro-radiology (KEM, Mumbai)
Consultant Radiologist (CT & MRI)

Address:- Morya Centre, 16/1, Race Course Road Indore
Authenticated by : RI

12/04/2018 19:33

Is brain atrophy curable?

"Treatment of brain atrophy. Since brain atrophy is the loss or damage of brain cell there is no treatment available to cure this complication. ... However, there are option slow the damage and improve physical ab that is hindered by brain atrophy." Jun 25, 2013

AI KRISHNA SUPERSPECIALITY NEURO HOSPITAL
STATION ROAD, KACHIGUDA, HYDERABAD-500027, PH: 040-44778899

EEG Report

| | | | |
|------------|------------|---------------|--------|
| Pt Name: | Ms. Arpita | Patient ID: | 0028 |
| Pat ID: | 140472 | Sex: | Female |
| Age: | 19 Years | Height: | |
| Physician: | P.G. Reddy | Technologist: | |

Technical Details:
EG was recorded using 10-20 International system of scalp electrode placement with minimal technical requirements. HV and Photic Stimulation were used as activation procedures.

Impression:
Ectopic and normal EEG activity seen.

Physician:
G. Reddy MD, DM
Consultant Neurologist

SODANI DIAGNOSTIC CLINIC
HO. : L.G-1, Morya Centre, Opp. Basket Ball Club, 16/1, Race Course Road, Indore (M.P.) | 0731-860-0201

Patient's Name : Ms. Arpita Chopra Date : 12/04/2018
Age / Sex : 19 Years / FEMALE Reg Date : 12/04/2018
Referred By : Dr.Chopra Arpit Reported : 12/04/2018 11:30

EEG PROTOCOL
This is a 32-channel EEG record obtained using 10-20 International system of electrode placements. Photo stimulation & hyperventilation were used as activation procedures.

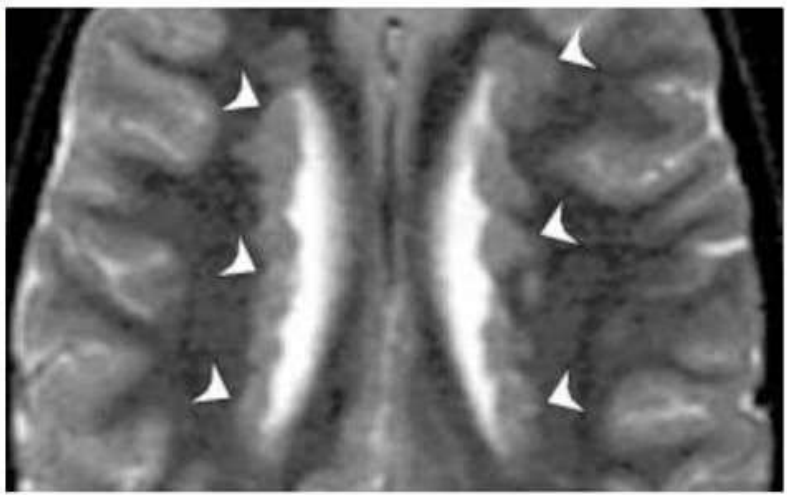
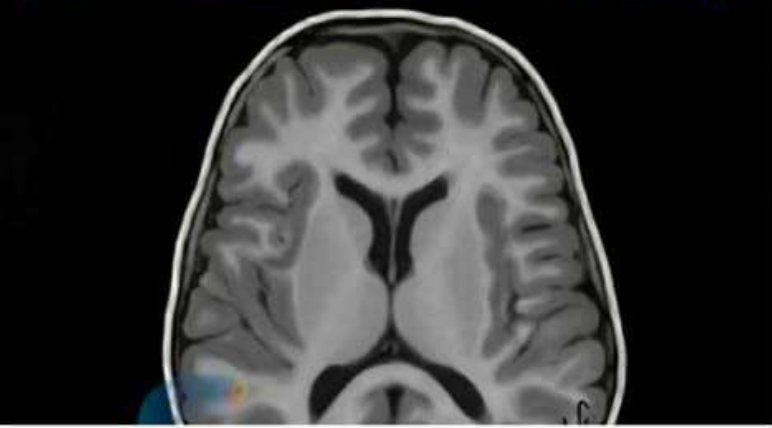
EEG REPORT
No epileptiform activity seen. Found within normal limits. Large

Impression :-
Kindly Correlate Clinically

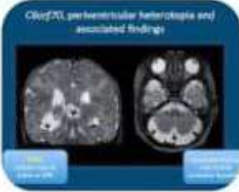
Dr. Prashant Joshi
MD DNB MNAMS
Physician & Neurologist

Authenticated by : RI

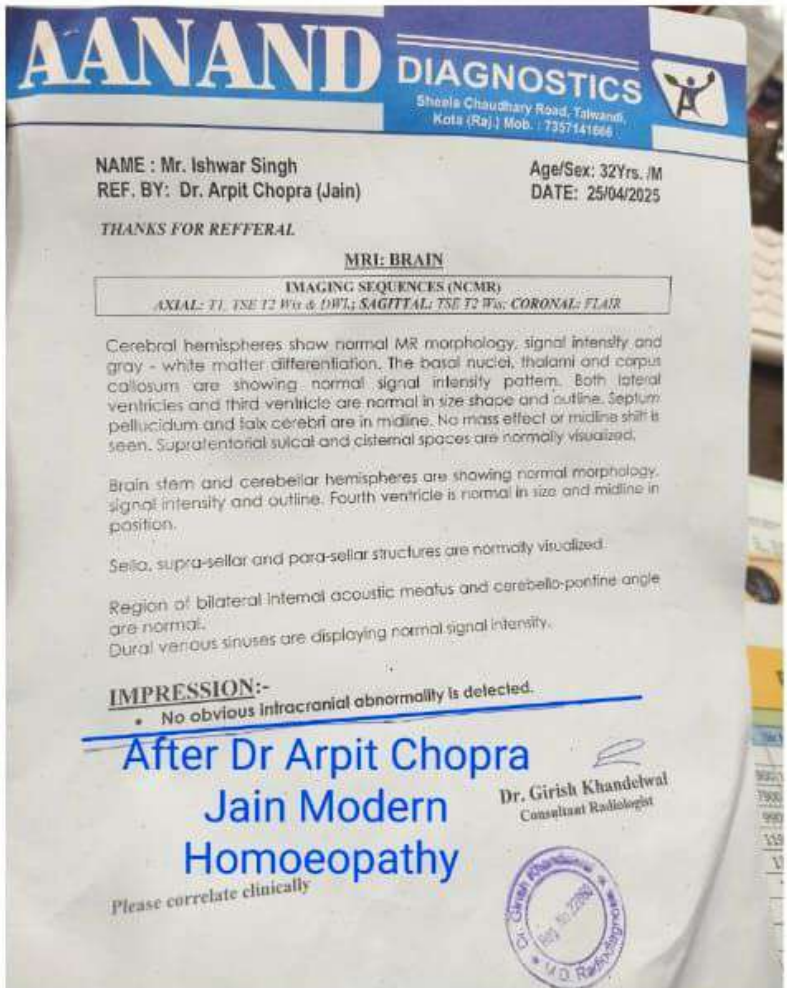
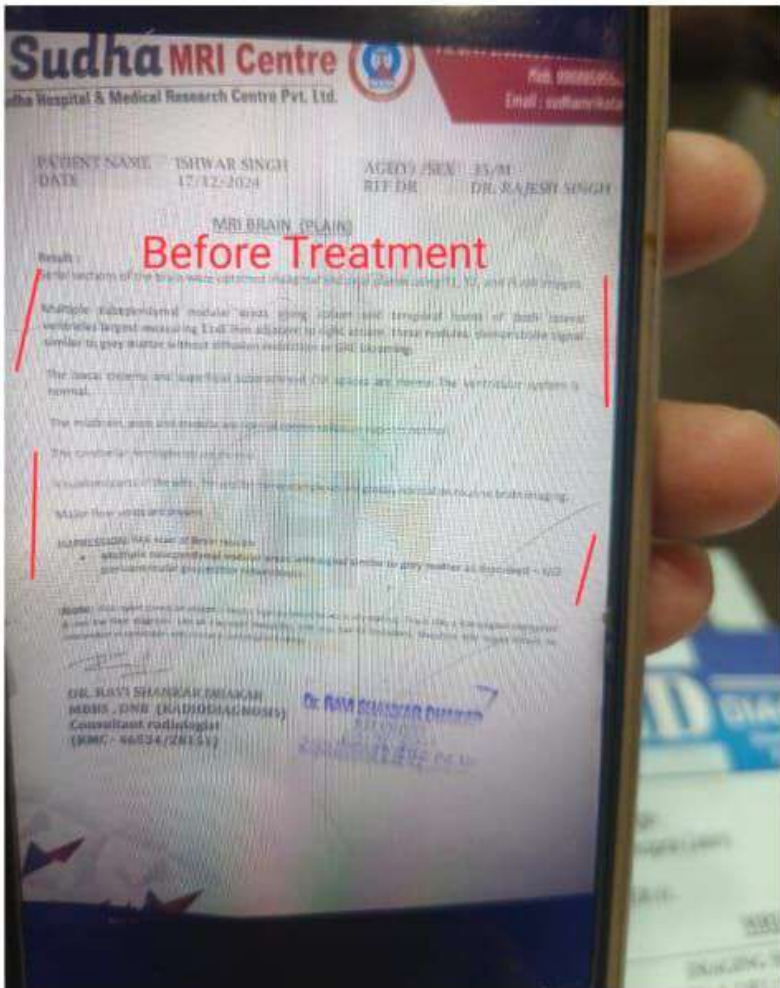
Periventricular Nodular Heterotopia



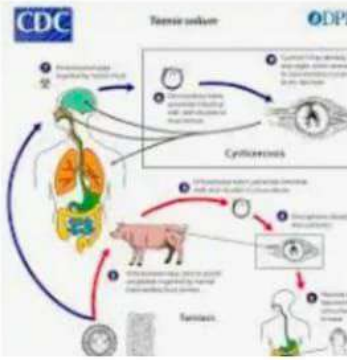
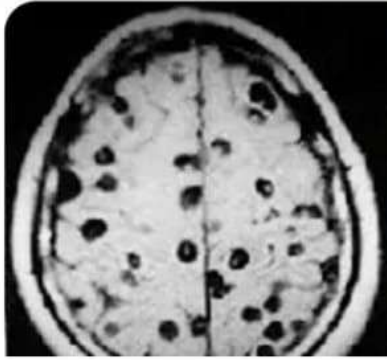
Periventricular heterotopia (PH) is a condition where nerve cells (neurons) fail to migrate properly during brain development, resulting in clumps of misplaced neurons around the fluid-filled cavities (ventricles) of the brain. These clumps, or nodules, are composed of disoriented neurons that haven't reached their intended destination in the cerebral cortex. PH can cause seizures, intellectual disabilities, and other neurological problems.



Neurological Diseases



Neurocysticercosis



Before Treatment

City Homoeopathy
After Dr Arpit Chopra Jain Modern TSC23homoeopathy



EPILEPSY CURE
NEUROCYSTICER

दिमाग में कीड़ा (न्यूरोसिस्टीसर्कोसिस) का इलाज क्या है? डॉक्टर से

(18-20 in number).
LARGEST MEASURES 7x6 mm (28/5/24).
SMALL AREAS OF SUSCEPTIBILITY. BLOOMING foci in LENTIFORM NUCLEUS & LEFT

MAX Healthcare

| | |
|-----------------------------|-------------------------------------------------|
| Patient Name: Hetesh Kumar | Location: MAX SUPER SPECIALITY HOSPITAL - SAKET |
| Age/Sex: 23/M | IP No.: Admission Type: OutPatient |
| Max ID: SKMS.0670884 | Order Date: 28-MAY-2024 |
| Ref. Doctor: J. D. Mukherji | Report Date: 28-MAY-2024 02:08 PM |

MRI Brain (Contrast) of 28-MAY-2024:
Results:
Serial sections of the brain were obtained in sagittal, coronal and axial planes using T1, T2, and FLAIR images. Additional post contrast images were obtained in sagittal, axial and coronal planes.

Multiple (18 to 20 in number) ring enhancing lesions seen in left caudate nucleus and bilateral fronto-parietal regions, largest in right frontal parafalcine cortex measuring 7 x 6mm and left high frontal region measuring 7 x 5mm. Minimal perilesional edema is seen in the right frontal parafalcine region. Small areas of susceptibility blooming seen in left lentiform nucleus and left temporal white matter. Few of these lesions reveal internal scolex.

Rest of the brain parenchyma shows normal MR morphology and gray-white differentiation.

The basal cisterns and superficial subarachnoid CSF spaces are normal.

The ventricular system is normal.

The midbrain, pons and medulla are normal.

The cerebellar hemispheres are normal.

Visualized parts of the sella, 5th, 7th and 8th nerve complexes are grossly normal on routine brain imaging.
Major flow voids are present.

Before Treatment

IMPRESSION: MR findings reveal:-
- Multiple ring enhancing lesions suggestive of neurocysticercosis in left caudate nucleus and bilateral fronto-parietal regions with minimal perilesional edema in the right frontal parafalcine region. Small areas of susceptibility blooming / calcific foci in left lentiform nucleus and left temporal white matter.

Dr. Amit Kumar
Principal Consultant

Report Approved / Verified Date & Time: 28-MAY-2024 02:08 PM

UNIQUE DIAGNOSTICS & RESEARCH CENTRE

Date: 17/02/2025
Name: MR. HETESH KUMAR
Ref. By: MAX HOSPITAL

Age: 24 Yrs. Sex: M

MRI BRAIN+CONTRAST

PROTOCOLS: Axial T1WSE, FSE-T2W and FLAIR pulse sequences. Coronal FLAIR & Sagittal FSE-T2W pulse sequence. DWI is also performed on 1.5 Tesla HD scanner. Post contrast T1W images were obtained in multiple planes.

Multiple tiny foci of T2/FLAIR hyperintensity are seen scattered in bilateral cerebral hemispheres and left basal ganglia with GRE blooming in few of them without surrounding edema. On post contrast images peripheral ring enhancement and solid nodular enhancement seen without meningeal enhancement, largest measuring approx. 6.5 x 4.5mm in left parietal region.

Remaining supratentorial neuroparenchyma appear normal.

Right basal ganglia, bilateral thalami and internal capsules are unremarkable.

The cerebellum and brain stem are normal.

Bilateral lateral, third & fourth ventricles are normal with no evidence of hydrocephalus.

There is no evidence of any abnormal meningeal enhancement or any enhancing exudates.

Cisterna magna is mild dilated.

Rest of the basal cisterns, fissures and sulci are normal.

Major dural venous sinuses show normal flow voids.

Pituitary gland appears normal in size and signal intensity for age.

Mild deviated nasal septum seen towards right side with mild hypertrophy of left inferior nasal turbinate.

IMPRESSION: Findings are suggestive of
* Neurocysticercosis in nodular calcified and granular nodular stage without surrounding edema.

Please correlate clinically.

During Dr Arpit Chopra Jain Modern Homoeopathy

DR. ANIL KUMAR VERMA
MRBS, MD (EYE), DIAGNOSIS
Special Investigations - Lab Investigations - ECHO Cardiography - ECG - EEG - PFT

आरोग्य सुपर स्पेशलिटी मॉडर्न होम्योपैथीक क्लिनिक
AAROGYA SUPER SPECIALITY MODERN HOMOEOPATHIC CLINIC

हमारी कोई अन्य शाखा नहीं है
प्रति कॉल में सहायता रहे

कैंसर, किडनी फेलियर, अस्पताल में गंभीर रूप से चली गयीं का उपचार, कोमा, मानस विकारों का योग्य अल्ट्रासोनिक सेन, अल्पास्थिक एंजायमिया, मस्कुलर डिस्ट्रॉफी, जीवन्त भर दवा लेने वाले रोगीक रोकथाम एवं 300 प्रकार के अरुण उपचार रोगी की विशिष्टता

0731-4977076 | 91 99075-27914, 91 97130-92737, 91 97130-37737, 91 93404-95872, 91 79999-78994 | 91 97130-37737, 91 80451-32033

Address: 101, 102, 103, 104, Krishna Tower, Janjeerwala Square, in front of Curewell Hospital Road, New Palasia, Indore, Madhya Pradesh 452001
Email: arpit@chopra23@gmail.com

DR. ARPIT CHOPRA JAIN
MD (HOMOEOPATHY) & CERTIFIED IN SURGICAL DISEASE SPECIALIST



Dept. of Radio-diagnosis & Imaging Services
CHOITHRAM HOSPITAL & RESEARCH CENTRE
MANIK BAGH ROAD, INDORE - 452 014 (M.P.) India

DEPARTMENT OF RADIO-DIAGNOSIS AND IMAGING SCIENCES

| | | | |
|--------------|------------------------|----------|-------------------------|
| PATIENT NAME | Mrs. SHYAMA BAI RATHOD | REC NO. | 15C31010444 |
| REG NO. | 1536537 | IR/OF | |
| AGE | 48 Y 1 D | SEX | FEMALE |
| REFERRED BY | DR. DHANRAJ PANJWANI | TEST NO. | 15D0503127 |
| WARD | | CASE | H/C |
| PRINT DATE | 25/08/2015 | ROOM | BED |
| REPORTED BY | DR. RAVINDRA SINGH | TIME | 11:58:53 AM |
| | | CATEGORY | PRINTED BY SURBHI RATHI |
| | | | CASH |

CT HEAD WITH CONTRAST Before Treatment

Technique:-Serial axial scans have been taken from the base of skull to the vertex on ultra fast 40 slice CT scanner, before & after contrast administration.

Findings:-

A couple of calcified nodular seen in left posterior parietal and occipital region with no obvious perifocal edema.No abnormal enhancement. These are measuring 8x6 and 5x6 mm?
Granulomatous.

After treatment

| | | | |
|------------|-----------------------|----------|-------------|
| Pt. Name : | MRS. SHYAMA BAI | Age/Sex: | 50Yrs/F. |
| Ref. By : | DR. ARPIT CHOPRA JAIN | Date : | 23/May/2016 |

MULTISLICE SPIRAL CECT SCAN BRAIN

Enhanced axial sections have been obtained from the base of skull to vertex.

No evidence of any intra cerebral SOL or mass effect is seen.

IMPRESSION:- CT findings reveal small nodular meningeal calcifications in left parietal region without any surrounding edema,?Physiological, ?? Old healed granulomas. No mass effect seen.

Want To Treat

MIGRAINE

Permanently



12:36

Dr. Arpit Chopda Jain

आरोग्य सुपर स्पेशलिटी
मार्डन होम्योपैथिक क्लीनिक
Dr. Arpit Chopra (Jain)
M.D. HOMOEOPATHY
(CRITICAL & SURGICAL DISEASES SPECIALIST)
9907527914, 97130927

विशेषताएं

कैंसर, किडनी फैलियर, गंभीर रूप से भर्ती मरीजों कोमा, ऑटो इम्यून रोग, शोथ, योग्य रोग, हायपोथायराइडिज्म, बालों का झड़ना, एजीमा, व्यसन मुक्ति, चर्म रोग, एसीडिटी, ल्यूकोडर्मा, माइग्रेन, गुम, साइनूसाइटिस, एनिमिया, ल, गठिया, अस्थमा एवं श्वसन होम्योपैथिक प्रतिरोधक ए टिटनेस, नपूसंकता, मुहांसे, साइटिका, डिप्रेशन मानसिक मलेरिया, मासिक रोग, डायबिटिज एवं गुर्दा, टायफाइड, टोन्सिलाईटिस, असाध्य रोग इत्यादि का त्वरित



कैंसर, किडनी फेलियर, अस्पताल में गंभीर रूप से भर्ती मरिजों का उपचार, कोमा, शल्य चिकित्सा योग्य रोग, ऑटो इम्यून रोग, जीवनभर दवाई लेने वाले रोगों की रोकथाम एवं 300 प्रकार के असाध्य जटिल रोगों की चिकित्सा।



डॉ. अर्पित चौपड़ा (जैन)
एम. बी. होम्योपैथी
जटिल, असाध्य एवं
शल्य रोग विशेषज्ञ

आरोग्य सुपर स्पेशलिटी मॉडर्न होमियोपैथी

कम्पलिट, परमानेन्ट, ईजी, सेफ, फास्ट एण्ड कॉस्ट इफेक्टिव

102, प्रथम मंजिल, कृष्णा टॉवर, कयोस्वेल हॉस्पिटल के सामने, जंजीरवाला चौराहा, न्यू पलासिया, इन्दौर म.प्र.

📞 99075 27914 संपर्क : 0731-4977076, 79999 78894

www.homoeopathycure.in, www.aarogyahomoeopathyindore.com Email : arpitchopra23@gmail.com



JULIE
2021 March 24
12 SATURDAY, JUL 12
Smoking Deaddiction
मैं अद्विग जोशी इन्दौर मे हूँ। मुझे धूम्रपान
कि आदत थी जब से मैं 10th class मे था।
तब से मे धूम्रपान करना था। फिर 2021
कि शुरुआत मे मुझे आरोग्य सुपर
स्पेशलिटी मॉडर्न होम्योपैथीक क्लीनिक
जा पत्ता पडा फिर डॉ अर्पित चौपड़ा
जी कि मदद से मैने 1-1/2 month मे
इस से निजात पालीया आज 2 Month
से मे धूम्रपान से दूर हूँ। मैरिना अब
मुझे करने कि संवर से इच्छा होती है।
36, तिलक पथ
इन्दौर
राज्यवाद
7997536493
13 SUNDAY

DEADDICTION
NO SMOKING



कैंसर, किडनी फेलियर, अस्पताल में गंभीर रूप से भर्ती मरिजों का उपचार, कोमा, शल्य चिकित्सा योग्य रोग, ऑटो इम्यून रोग, जीवनभर दवाई लेने वाले रोगों की रोकथाम एवं 300 प्रकार के असाध्य जटिल रोगों की चिकित्सा।



आरोग्य सुपर स्पेशलिटी मॉडर्न होमियोपैथी

कम्पलिट, परमानेंट, ईजी, सेफ, फास्ट एण्ड कॉस्ट इफैक्टिव

102, प्रथम मंजिल, कृष्णा टॉवर, क्योरवेल हॉस्पिटल के सामने, जंजीरवाला चौराहा, न्यू पलासिया, इन्दौर म.प्र.

📞 99075 27914 संपर्क : 0731-4977076, 79999 78894

www.homoeopathy cure.in, www.aarogyahomoeopathyindore.com Email : arpitchopra23@gmail.com


Neuromuscular disorders affect your neuromuscular system. They can cause problems with

- The nerves that control your muscles
- Your muscles
- Communication between your nerves and muscles

These disorders can cause your muscles to become weak and waste away. You may also have symptoms such as spasms, twitching, and pain.

Examples of neuromuscular disorders include

- Amyotrophic lateral sclerosis
- Muscular dystrophy
- Myasthenia gravis
- Spinal muscular atrophy



Neuromuscular disorder (NMD) is a broad term encompassing a range of conditions that impair the function of the muscles, either directly, being pathologies of the voluntary muscles or indirectly, being pathologies of the peripheral nervous system or neuromuscular junctions. 24-Feb

क्या आप न्यूरो मस्क्युलर डिजीसेस से परेशान हैं



न्यूरो मस्क्युलर डिजीसेस कैसे खत्म करे

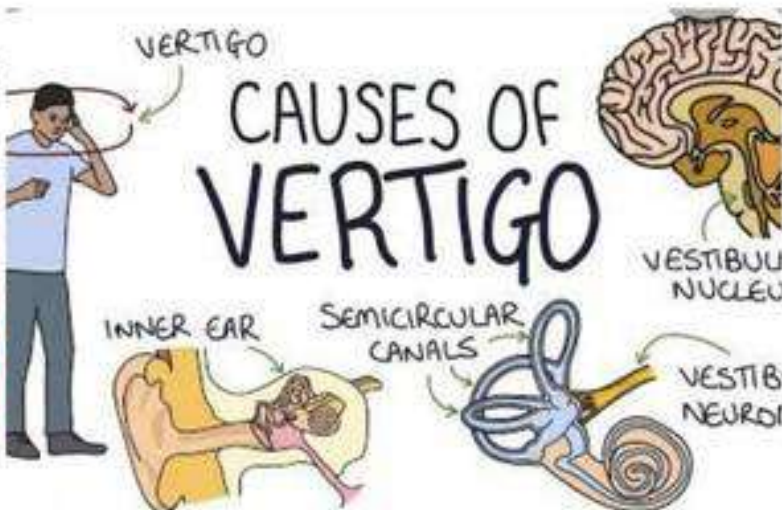Epidemiology of Neuromuscular Diseases



PREMIERING NOW

Patient - Priya

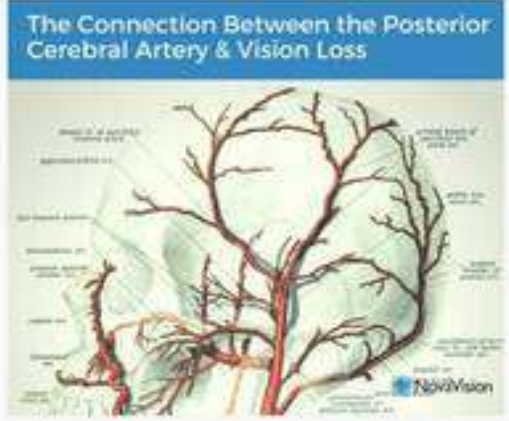
Treatment Of Neuro-Muscular Diseases By Modern Homoeopathy



What happens if posterior cerebral artery is occluded?



Occlusions of the branches of the PCA that supply the thalamus can result in **central post-stroke pain and lesions to the subthalamic branches** can produce "a wide variety of deficits". Left posterior cerebral artery syndrome presents alexia without agraphia; the lesion is in the splenium of the corpus callosum.



Various types of vision deficits can occur

आरोग्य सुपर स्पेशलिटी मॉडर्न होम्योपैथिक क्लीनिक

डॉ. अर्पित चोपड़ा

डिप्लोमेट • पारामेडिक • इंजी • मेड • फाट एण्ड डॉस्ट इकेविल

• फिलर • किडनी फेलियर • अस्पायल में सर्जरी रूप से • भर्ती भरिओ का उपचार • कोचा
 • रक्तम विकिरण रोग्य रोग • छोटे ड्रग्स रोग • जीवनभर ट्वाई लेने वाले रोगों की रोकथाम
 एवं 100 प्रकार के अत्यंत खतरनाक रोगों की चिकित्सा ।

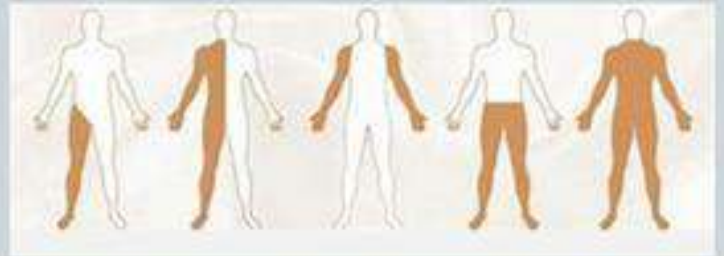
102, 104 प्रथम मंजिल, कुल्हा टॉवर, सर्वोपेक्ष होस्पिटल के सामने, जंजीरवाला चौक, न्यू पल्लविका, इन्डौर (म.प्र.)
 फोन : 0731-4972078, मो. : 97130-92737, 97130-37737, 79999-78894, 99078-27914
 www.homoecopathycare.in, www.aarogyaahomeopathyindore.com Email : arpit@chopra23@gmail.com
 dr arpit chopra's super speciality modern homeopathic, https://g.page/CaRz32wBZQXBA



4/0 Peti Vaccination complication
 1st date : 24 March
 - Diminution of vision (both eyes)
 - DM type II
 - Dyslipidemia
 - Rt PCA occlusion
 4/0 -> left eye e. glaucoma
 -> Pain in digit

हस्त - 5.1 (Apr 21)
 20
 20 to 25
 20 to 25

Paralysis

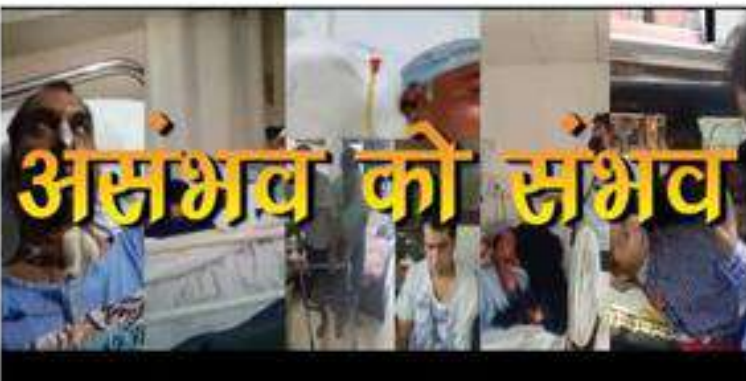
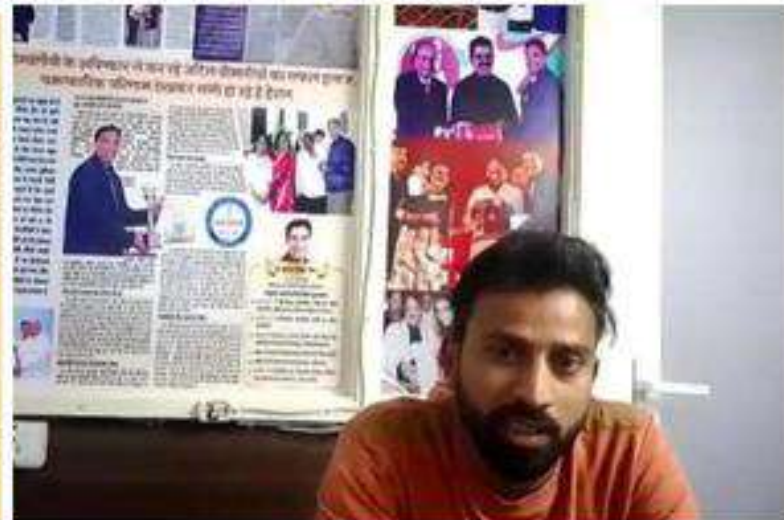
पक्षाघात या लकवा की
समस्या कारण, लक्षण और
उपचार

Neurological Disorders

Symptoms, Causes
and Complications

What are the most
common neurological
problems?



NO SURGERY
LIFE SPARING
NO SIDE EFFECTS
FAST TREATMENT
PERMANENT CURE
NON-DRUG THERAPY

ALL TYPES OF BRAIN RELATED PROBLEMS CURED BY DR. ARPIT CHOPRA, JAIN'S MODERN HOMIOPATHY

मॉडर्न होम्योपैथी
 Complete Homeopathy, Complete, Permanent, Easy, Safe, Fast & Cost-Effective

Migraine Cured Succ...

Raghunath Singh Verma
 Patient

Dr. Arpit Chopra (Jain)
 M.D. (HOMEOPATHY)
 M.D. (SURGICAL DENTISTRY)
 Master of Science Specialty Modern Homeopathy

AAROGYA SUPERSPECIALITY MODERN HOMEO
 Complete, Safe, Fast & Cost-Effective Modern Homeopathy Care!
 Phone : 0731-4977076, Mobile : 97130-92737, 97130-37737, 79999-2

क्या आम ट्राइजिमेनल न्यूराल्जिया से परेशान हैं? ट्राइजिमेनल न्यूराल्जिया कैसे खत्म करें?

Patient - Nandini Chipe
 Dr. Arpit Chopra

AAROGYA SUPERSPECIALITY MODERN HOMEO
 Complete, Safe, Fast & Cost-Effective Modern Homeopathy Care!
 Phone : 0731-4977076, Mobile : 97130-92737, 97130-37737, 79999-2

ONDYLITHIS, RHEUMATOID ARTHRITIS, SP

कैंसर, किडनी फेलियर, अस्पताल में गंभीर रूप से भर्ती मरिजों का उपचार, कोमा, शल्य चिकित्सा योग्य रोग, ऑटो इम्यून रोग, जीवनभर दवाई लेने वाले रोगों की रोकथाम एवं 300 प्रकार के असाध्य जटिल रोगों की चिकित्सा।

आरोग्य सुपर स्पेशलिटी मॉडर्न होमियोपेथी
 कम्प्लिट, परमानेन्ट, ईजी, सेफ, फास्ट एण्ड कॉस्ट इफैक्टिव

102, प्रथम मंजिल, कृष्णा टॉवर, क्योरवेल हॉस्पिटल के सामने, जंजीरवाला चौराहा, न्यू पलासिया, इन्दौर म.प्र.
 99075 27914 संपर्क : 0731-4977076, 79999 78894
 www.homoeopathyinindia.com, www.aarogyahomoeopathyindore.com Email : arpitchopra23@gmail.com

21:47

मॉडर्न होम्योपैथी

Modern Homeopathy - Complete, Permanent, Easy, Safe, Fast & Cost Effective



Nitika Mehara
Indore

Migraine

Dr. Arpit Chopra (Jain) AAROGYA SUPERSPECIALITY MODERN HOMEOPATHY CLINIC
(MD) HOMEOPATHY
CRITICAL & SURGICAL DISEASIS SPECIALIST
Inventor Of Super Speciality Modern Homeopathy
Complete, Safe, Fast & Cost-Effective Modern Homeopathy Cured With Advanced Lifestyle
-Phone : 0731-4977076, Mobile : 97130-92737, 97130-37737, 79999-78894, For Whatsapp

22:28

PHYLAXIS, TETANUS, ALLERGY, SKIN DISEASES, LUZEM

MIGRAINE

Dr. Arpit Chopra (Jain) AAROGYA SUPERSPECIALITY MODERN HOMEOPATHY CLINIC
Complete, Safe, Fast & Cost-Effective Modern Homeopathy Cured With Advanced Lifestyle
-Phone : 0731-4977076, Mobile : 97130-92737, 97130-37737, 79999-78894, For Whatsapp

होम्योपैथी

Permanent, Easy, Safe, Fast & Cost Effective

AAROGYA SUPERSPECIALITY MODERN HOMEOPATHY CLINIC
Complete, Safe, Fast & Cost-Effective Modern Homeopathy Cured With Advanced Lifestyle
-Phone : 0731-4977076, Mobile : 97130-92737, 97130-37737, 79999-78894, For Whatsapp

मॉडर्न होम्योपैथी

Modern Homeopathy - Complete, Permanent, Easy, Safe, Fast & Cost Effective Cure



Simran Yadav

Indore (M.P.)

Dr. Arpit Chopra (Jain)
(MD) HOMEOPATHY

CRITICAL & SURGICAL DISEASES SPECIALIST
Inventor Of Super Speciality Modern Homeopathy

AROGYA SUPERSPECIALITY MODERN HOMEOPATHY CLINIC

Complete, Safe, Fast & Cost-Effective Modern Homeopathy Cured With Advanced Lifestyle

Phone : 0731-4977076, Mobile : 97130-92737, 97130-37737, 79999-78894, For Whassaap, 99075-27914

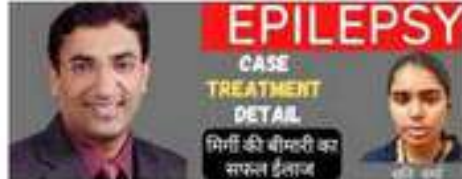AROGYA SI



Cerebral Atrophy with Epilepsy ...



Cerebral Atrophy with Epilepsy ...

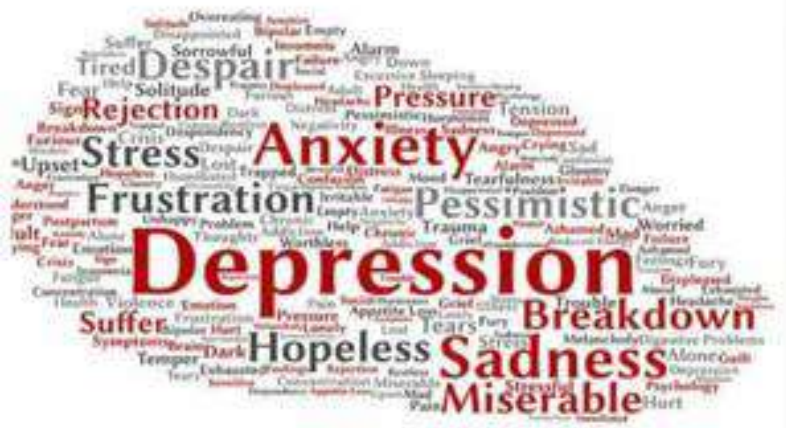

EPILEPSY

CASE
TREATMENT
DETAIL

मिर्ची की बीमारी का सफल इलाज





मॉडर्न होम्योपैथी

Modern Homeopathy • Computerized, Personalized, Easy, Safe, Fast & Cost Effective



DR. RINA MORE

आरोग्य

RINA MORE

AAROGYA SUPERSPECIALITY MODERN HOMEOPATHIC CLINIC
 Complete, Safe, Fast & Cost Effective Personalized Modern Homeopathy Care with Advanced Clinical
 Phone : 0731-4977076, Mobile : 97135-92137, 97135-27737, 79999-76894, 990752714

DISORDERS, CHRONIC DISORDERS, EXCESSIVE SWEATING

मॉडर्न होम्योपैथी

Modern Homeopathy • Computerized, Personalized, Easy, Safe, Fast & Cost Effective



DR. ABID HUSSAIN

आरोग्य

ABID HUSSAIN

AAROGYA SUPERSPECIALITY MODERN HOMEOPATHIC CLINIC
 Complete, Safe, Fast & Cost Effective Personalized Modern Homeopathy Care with Advanced Clinical
 Phone : 0731-4977076, Mobile : 97135-92137, 97135-27737, 79999-76894, 990752714

मॉडर्न होम्योपैथी

Modern Homeopathy • Computerized, Personalized, Easy, Safe, Fast & Cost Effective



DR. ANIL CHOPRA

आरोग्य

ANIL CHOPRA

AAROGYA SUPERSPECIALITY MODERN HOMEOPATHIC CLINIC
 Complete, Safe, Fast & Cost Effective Personalized Modern Homeopathy Care with Advanced Clinical
 Phone : 0731-4977076, Mobile : 97135-92137, 97135-27737, 79999-76894, 990752714

मॉडर्न होम्योपैथी

Modern Homeopathy • Computerized, Personalized, Easy, Safe, Fast & Cost Effective



DR. ANIL CHOPRA

आरोग्य

ANIL CHOPRA

AAROGYA SUPERSPECIALITY MODERN HOMEOPATHIC CLINIC
 Complete, Safe, Fast & Cost Effective Personalized Modern Homeopathy Care with Advanced Clinical
 Phone : 0731-4977076, Mobile : 97135-92137, 97135-27737, 79999-76894, 990752714

कैसर, किडनी फेलियर, अस्पताल में गंभीर रूप से भर्ती मरिजों का उपचार, कोमा, शल्य चिकित्सा योग्य रोग, ऑटो इम्यून रोग, जीवनभर दवाई लेने वाले रोगों की रोकथाम एवं 300 प्रकार के असाध्य जटिल रोगों की चिकित्सा ।

आरोग्य सुपर स्पेशलिटी मॉडर्न होमियोपैथी

कम्प्लिट, परमानेंट, इंजी, सेफ, फास्ट एण्ड कॉस्ट इफेक्टिव

102, प्रथम मंजिल, कृष्णा टॉवर, ब्योरस्पेल हॉस्पिटल के सामने, जंजीरवाला चौराहा, न्यू पलारिया, इन्डौर म.प्र.

99075 27914 संपर्क : 0731-4977076, 79999 76894



कैंसर, किडनी फेलियर, अस्पताल में गंभीर रूप से भर्ती मरिजों का उपचार, कोमा, शल्य चिकित्सा योग्य रोग, ऑटो इम्यून रोग, जीवनभर दवाई लेने वाले रोगों की रोकथाम एवं 300 प्रकार के असाध्य जटिल रोगों की चिकित्सा ।

आरोग्य सुपर स्पेशलिटी मॉडर्न होमियोपेथी
कम्प्लिट, परमानेंट, ईजी, सेफ, फास्ट एण्ड कॉस्ट इफैक्टिव

102, प्रथम मंजिल, कृष्णा टॉवर, सयोरवेल हॉस्पिटल के सामने, जंजीरवाला पौराहा, न्यू पलासिया, इन्दौर म.प्र.
99075 27914 संपर्क : 0731-4977076, 79990 78804
www.homeopathycure.in, www.saroqshomeopathyindore.com Email : arpitichopra23@gmail.com

रक्त के 5 बड़े कारण

रक्त का काला होना

Dr. Arpit Chopra Jain

पराधीन या असाध्य रोग (Paralysis) एक ही एकदम पराधीन रक्त की मरिजों के कारण करने में पूर्णतः असमर्थ होने की स्थिति को कहते हैं। पराधीन रक्त प्रभावी क्षेत्र की संश्लेषण-वर्धन कारण हो सकती है या उस क्षेत्र को शल्य चिकित्सा या पुराने असमर्थ हो कारण है। यदि दुर्भाग्यवश जटिल है तो सर्जिकल परामर्श करनी है।



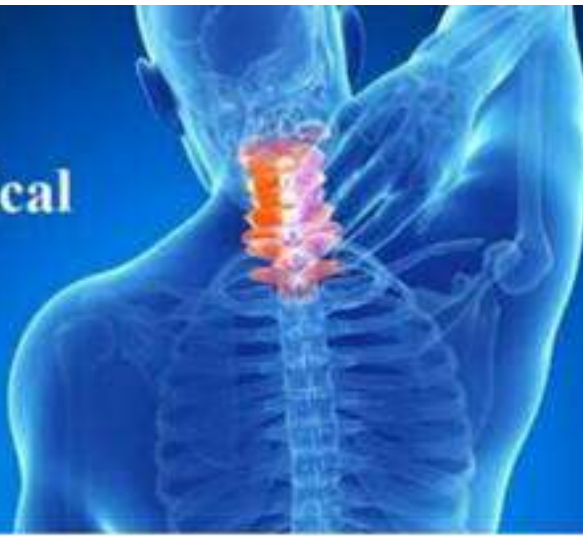Dr. Arpit Chopra Jain का रक्त का कारण
13 years responded by
Dr Arpit Chopra Jain Modern
Homeopathy

Dr. Arpit Chopra Jain ANALYTICS

12-13-14-15-16-17-18-19-20-21-22-23-24-25-26-27-28-29-30-31-32-33-34-35-36-37-38-39-40-41-42-43-44-45-46-47-48-49-50-51-52-53-54-55-56-57-58-59-60-61-62-63-64-65-66-67-68-69-70-71-72-73-74-75-76-77-78-79-80-81-82-83-84-85-86-87-88-89-90-91-92-93-94-95-96-97-98-99-100-101-102-103-104-105-106-107-108-109-110-111-112-113-114-115-116-117-118-119-120-121-122-123-124-125-126-127-128-129-130-131-132-133-134-135-136-137-138-139-140-141-142-143-144-145-146-147-148-149-150-151-152-153-154-155-156-157-158-159-160-161-162-163-164-165-166-167-168-169-170-171-172-173-174-175-176-177-178-179-180-181-182-183-184-185-186-187-188-189-190-191-192-193-194-195-196-197-198-199-200-201-202-203-204-205-206-207-208-209-210-211-212-213-214-215-216-217-218-219-220-221-222-223-224-225-226-227-228-229-230-231-232-233-234-235-236-237-238-239-240-241-242-243-244-245-246-247-248-249-250-251-252-253-254-255-256-257-258-259-260-261-262-263-264-265-266-267-268-269-270-271-272-273-274-275-276-277-278-279-280-281-282-283-284-285-286-287-288-289-290-291-292-293-294-295-296-297-298-299-300-301-302-303-304-305-306-307-308-309-310-311-312-313-314-315-316-317-318-319-320-321-322-323-324-325-326-327-328-329-330-331-332-333-334-335-336-337-338-339-340-341-342-343-344-345-346-347-348-349-350-351-352-353-354-355-356-357-358-359-360-361-362-363-364-365-366-367-368-369-370-371-372-373-374-375-376-377-378-379-380-381-382-383-384-385-386-387-388-389-390-391-392-393-394-395-396-397-398-399-400-401-402-403-404-405-406-407-408-409-410-411-412-413-414-415-416-417-418-419-420-421-422-423-424-425-426-427-428-429-430-431-432-433-434-435-436-437-438-439-440-441-442-443-444-445-446-447-448-449-450-451-452-453-454-455-456-457-458-459-460-461-462-463-464-465-466-467-468-469-470-471-472-473-474-475-476-477-478-479-480-481-482-483-484-485-486-487-488-489-490-491-492-493-494-495-496-497-498-499-500-501-502-503-504-505-506-507-508-509-510-511-512-513-514-515-516-517-518-519-520-521-522-523-524-525-526-527-528-529-530-531-532-533-534-535-536-537-538-539-540-541-542-543-544-545-546-547-548-549-550-551-552-553-554-555-556-557-558-559-560-561-562-563-564-565-566-567-568-569-570-571-572-573-574-575-576-577-578-579-580-581-582-583-584-585-586-587-588-589-590-591-592-593-594-595-596-597-598-599-600-601-602-603-604-605-606-607-608-609-610-611-612-613-614-615-616-617-618-619-620-621-622-623-624-625-626-627-628-629-630-631-632-633-634-635-636-637-638-639-640-641-642-643-644-645-646-647-648-649-650-651-652-653-654-655-656-657-658-659-660-661-662-663-664-665-666-667-668-669-670-671-672-673-674-675-676-677-678-679-680-681-682-683-684-685-686-687-688-689-690-691-692-693-694-695-696-697-698-699-700-701-702-703-704-705-706-707-708-709-710-711-712-713-714-715-716-717-718-719-720-721-722-723-724-725-726-727-728-729-730-731-732-733-734-735-736-737-738-739-740-741-742-743-744-745-746-747-748-749-750-751-752-753-754-755-756-757-758-759-760-761-762-763-764-765-766-767-768-769-770-771-772-773-774-775-776-777-778-779-780-781-782-783-784-785-786-787-788-789-790-791-792-793-794-795-796-797-798-799-800-801-802-803-804-805-806-807-808-809-810-811-812-813-814-815-816-817-818-819-820-821-822-823-824-825-826-827-828-829-830-831-832-833-834-835-836-837-838-839-840-841-842-843-844-845-846-847-848-849-850-851-852-853-854-855-856-857-858-859-860-861-862-863-864-865-866-867-868-869-870-871-872-873-874-875-876-877-878-879-880-881-882-883-884-885-886-887-888-889-890-891-892-893-894-895-896-897-898-899-900-901-902-903-904-905-906-907-908-909-910-911-912-913-914-915-916-917-918-919-920-921-922-923-924-925-926-927-928-929-930-931-932-933-934-935-936-937-938-939-940-941-942-943-944-945-946-947-948-949-950-951-952-953-954-955-956-957-958-959-960-961-962-963-964-965-966-967-968-969-970-971-972-973-974-975-976-977-978-979-980-981-982-983-984-985-986-987-988-989-990-991-992-993-994-995-996-997-998-999-1000

Cervical

Spondylosis



मॉडर्न होम्योपैथी

Arpit Chopra (Jain)
 MD HOMEOPATHY
 CLINICAL INVESTIGATOR
 Super Speciality Modern Homeopathy

AAROGYA SUPERSPECIALITY MODERN HOMEOPATHY CLINIC
 Complete, Safe, Fast & Cost-Effective Modern Homeopathy Cured With Advanced Lifestyle
 Phone : 0731-4977076, Mobile : 97130-92737, 97130-37737, 79999-78894, For Whatsapp, 99075-27914

HEADACHE, NEURALGIA, MIGRAINE, KNEEPAIN, DIABETES, BREAST TUMOR & UTERINE

मॉडर्न होम्योपैथी

Arpit Chopra (Jain)
 MD HOMEOPATHY
 CLINICAL INVESTIGATOR
 Super Speciality Modern Homeopathy

AAROGYA SUPERSPECIALITY MODERN HOMEOPATHY CLINIC
 Complete, Safe, Fast & Cost-Effective Modern Homeopathy Cured With Advanced Lifestyle
 Phone : 0731-4977076, Mobile : 97130-92737, 97130-37737, 79999-78894, For Whatsapp, 99075-27914

POTENCY, SEXUALDISEASES, RHEUMATISM, BACKAC

मॉडर्न होम्योपैथी

Arpit Chopra (Jain)
 MD HOMEOPATHY
 CLINICAL INVESTIGATOR
 Super Speciality Modern Homeopathy

AAROGYA SUPERSPECIALITY MODERN HOMEOPATHY CLINIC
 Complete, Safe, Fast & Cost-Effective Modern Homeopathy Cured With Advanced Lifestyle
 Phone : 0731-4977076, Mobile : 97130-92737, 97130-37737, 79999-78894, For Whatsapp, 99075-27914

कैंसर, किडनी फेलियर, अस्पताल में गंभीर रूप से भर्ती महिलाओं का उपचार, कोमा, शल्य चिकित्सा योग्य रोग, आँटो इन्फ्लू रोग, जीवनभर दवाई लेने वाले रोगों की रोकथाम एवं 300 प्रकार के असाध्य जटिल रोगों की चिकित्सा।

आरोग्य सुपर स्पेशलिटी मॉडर्न होम्योपैथिक क्लिनिक

कम्प्लिट * परमानेंट * ईजी * सेफ * फास्ट एंड कॉस्ट इफैक्टिव

+ कैंसर + किडनी फेलियर + अस्पताल में गंभीर रूप से भर्ती महिलाओं का उपचार + कोमा + शल्य चिकित्सा योग्य रोग + आँटो इन्फ्लू रोग + जीवनभर दवाई लेने वाले रोगों की रोकथाम एवं 300 प्रकार के असाध्य जटिल रोगों की चिकित्सा।

102, 104 प्रथम बंगला, कृष्ण टॉवर, स्कोपेल हॉस्पिटल के सामने, जज्जीरवाला बौराड़ा, न्यू परागसिमा, इन्दौर (म.प्र.)
 फोन : 0731-4977076, मो. : 97130-92737, 97130-37737, 79999-78894, 99075-27914
 www.homeopathy.cure.in, www.aarogyahomeopathyindore.com Email : arpitchopra23@gmail.com

10.00 2009 के सबसे बड़े कामों
 11.00 पर 2024 का आगे से हमारा
 12.00 लक्ष्य रहेगा है, तब तक बना
 13.00 रहेगा है, क्योंकि बहुत से आ
 14.00 ये लक्ष्य में किसी भी
 15.00 मध्यम करेगा, जैसे कुछ
 16.00 2024 के में बहुत सारा
 17.00 धारणा था। इस कारण
 18.00 में आपका सामान्य जीवन
 19.00 बनी थी, पता था। अन्य
 20.00 प्रकार के प्रोग्रामों में
 21.00 के उपरोक्त बातों को तरह
 22.00 का आराम ही हुआ।

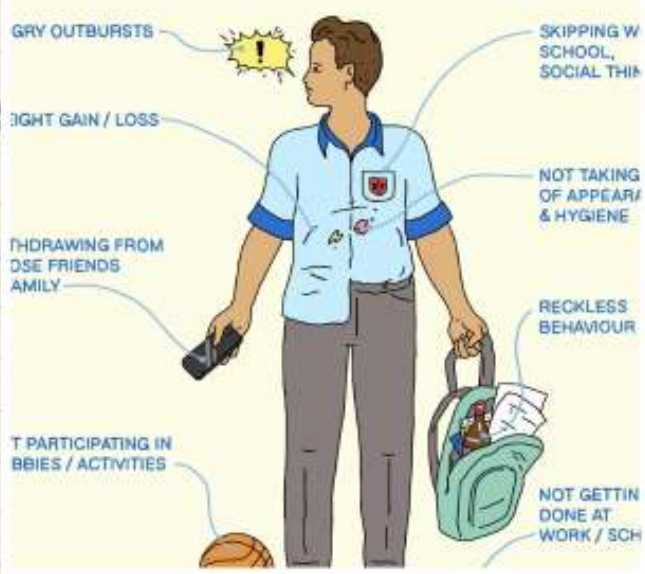18.00 परन्तु जब आपको
 19.00 क्षमता या पैसा का प्रोग्राम
 20.00 लिया मुझे करना है
 21.00 बहुत करके आराम मिल
 22.00 अथवा प्रोग्राम बने 5 वर्ष
 23.00 के प्रोग्राम का कर्तव्य
 24.00 था था, परन्तु हा. आपकी
 25.00 न्याय का पढ़ाया लेते से

1. महिला में फूलिया से रोक ले
 10.00 बच्चा और में अपना सामान्य
 11.00 जीवन जी पा रहा है अब
 12.00 अपना पारिवारिक आराम
 13.00 सामान्य रूप से पूरा तरह से
 14.00 निभा पा रहा है। मुझे
 15.00 बधाई है। इस कारण बहुत सारे
 16.00 देश के लोग में कर, का
 17.00 बच्चा - बहुत बच्चा है
 18.00 कि उन्होंने बहुत पूरा जीवन
 19.00 नकल। 17 सालों पढ़ाया अब
 20.00 उनके प्रोग्राम से बच्चा लिया
 21.00 बहुत - बहुत धन्यवाद कर

Sunday 23

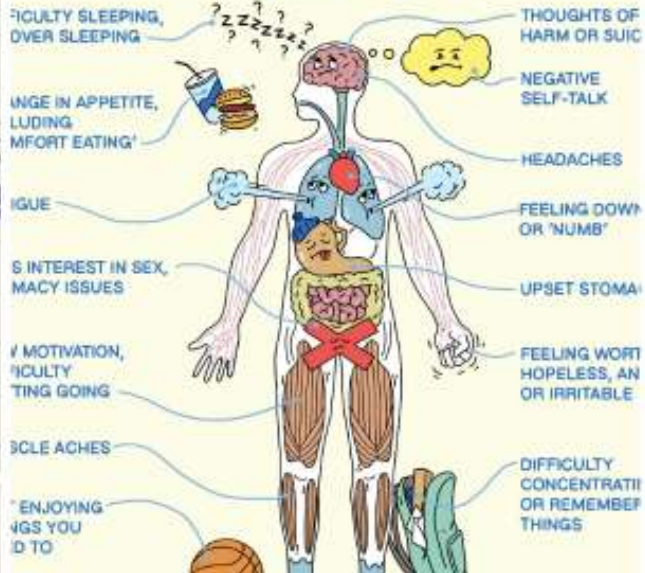SIGNS & SYMPTOMS OF DEPRESSIO

WHAT YOU SEE



SIGNS & SYMPTOMS OF DEPRESSIO

WHAT YOU DON'T SEE



आरोग्य सुपर स्पेशलिटी
 मॉडर्न होम्योपैथिक क्लिनिक
Dr. Arpit Chopra (Jain)
 M.D. HOMOEOPATHY
 (CRITICAL & SURGICAL DISEASES SPECIALIST)
 9907527914, 9713092737

विशेषताएं :

कैंसर, किडनी फैलियर, अस्पताल में गंभीर रूप से भर्ती मरीजों का उपचार, कोमा, ऑटो इम्यून रोग, शल्य चिकित्सा योग्य रोग, हायपोथायराइडिज्म, एलर्जी, बालों का झड़ना, एंजीमा, सोरायसीस, व्यसन मुक्ति, चर्म रोग, एसीडीटी, मोटापा, ल्यूकोडर्मा, माइग्रेन, गुप्तरोग, पथरी, साइनूसाइटिस, एनिमिया, लकवा, पाईल्स, गठिया, अस्थमा एवं श्वसन संबंधी रोग, होम्योपैथिक एडिपोजेनिक एवं होम्योपैथी

क्या आप डिप्रेशन से परेशान हैं



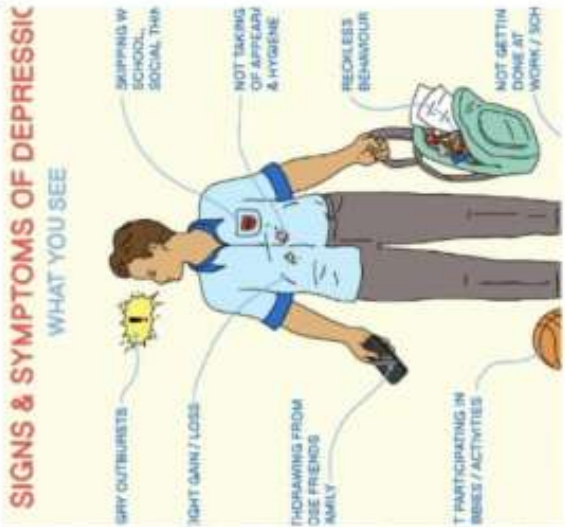डिप्रेशन को कैसे खत्म करे



Rahul Kumar

PREMIERE in

Treatment Of Depression By Modern Homeopathy



आरोग्य सुपर स्पेशलिटी
मॉडर्न होम्योपैथिक क्लीनिक
Dr. Arpita Chopra (Jain)
 M.D. HOMEOPATHY
 (CRITICAL & SURGICAL DISEASES SPECIALIST)
 9907527914, 9713092737

विशेषताएं :
 कैंसर, किडनी फेलियर, अस्पताल में गंभीर रूप से मर्ती मरीजों का उपचार, कोमा, ऑटो इम्यून रोग, शल्य चिकित्सा योग्य रोग, हायपोथायराइडिज्म, एलर्जी, बालों का झड़ना, एंजीमा, सोरायसीस,

1. 2009 के मरीजों में डिप्रेशन का प्रचलन बढ़ रहा है, जानिए क्यों
 2. डिप्रेशन को ठीक से समझना ही डिप्रेशन को ठीक से ठीक करने का रास्ता है।
 3. डिप्रेशन को ठीक करने के लिए आपको अपने जीवन में कुछ बदलाव करना पड़ेगा।
 4. डिप्रेशन को ठीक करने के लिए आपको अपने जीवन में कुछ बदलाव करना पड़ेगा।
 5. डिप्रेशन को ठीक करने के लिए आपको अपने जीवन में कुछ बदलाव करना पड़ेगा।
 6. डिप्रेशन को ठीक करने के लिए आपको अपने जीवन में कुछ बदलाव करना पड़ेगा।
 7. डिप्रेशन को ठीक करने के लिए आपको अपने जीवन में कुछ बदलाव करना पड़ेगा।
 8. डिप्रेशन को ठीक करने के लिए आपको अपने जीवन में कुछ बदलाव करना पड़ेगा।
 9. डिप्रेशन को ठीक करने के लिए आपको अपने जीवन में कुछ बदलाव करना पड़ेगा।
 10. डिप्रेशन को ठीक करने के लिए आपको अपने जीवन में कुछ बदलाव करना पड़ेगा।

1. 2009 के मरीजों में डिप्रेशन का प्रचलन बढ़ रहा है, जानिए क्यों
 2. डिप्रेशन को ठीक से समझना ही डिप्रेशन को ठीक से ठीक करने का रास्ता है।
 3. डिप्रेशन को ठीक करने के लिए आपको अपने जीवन में कुछ बदलाव करना पड़ेगा।
 4. डिप्रेशन को ठीक करने के लिए आपको अपने जीवन में कुछ बदलाव करना पड़ेगा।
 5. डिप्रेशन को ठीक करने के लिए आपको अपने जीवन में कुछ बदलाव करना पड़ेगा।
 6. डिप्रेशन को ठीक करने के लिए आपको अपने जीवन में कुछ बदलाव करना पड़ेगा।
 7. डिप्रेशन को ठीक करने के लिए आपको अपने जीवन में कुछ बदलाव करना पड़ेगा।
 8. डिप्रेशन को ठीक करने के लिए आपको अपने जीवन में कुछ बदलाव करना पड़ेगा।
 9. डिप्रेशन को ठीक करने के लिए आपको अपने जीवन में कुछ बदलाव करना पड़ेगा।
 10. डिप्रेशन को ठीक करने के लिए आपको अपने जीवन में कुछ बदलाव करना पड़ेगा।

Complications of Insomnia

Psychological

- Lower performance
- Slowed reaction time
- Risk of depression
- Risk of anxiety disorder

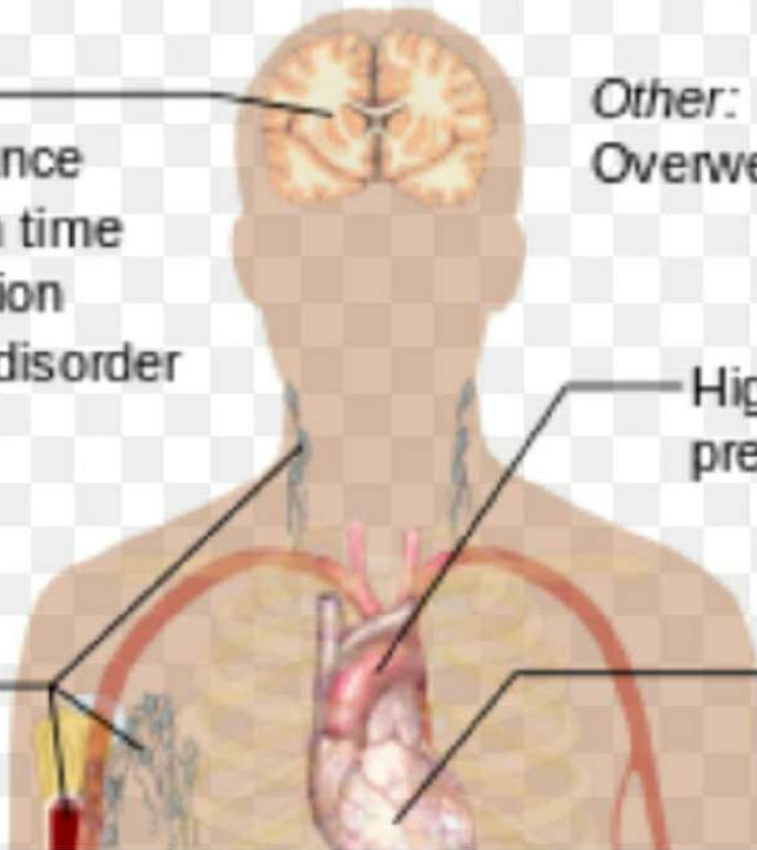
Other:

Overweight or obesity

High blood pressure

Poor immune system function

Risk of heart disease



Insomnia

ABOUT

SYMPTOMS

TREATMENTS




Difficulty falling asleep results in daytime drowsiness

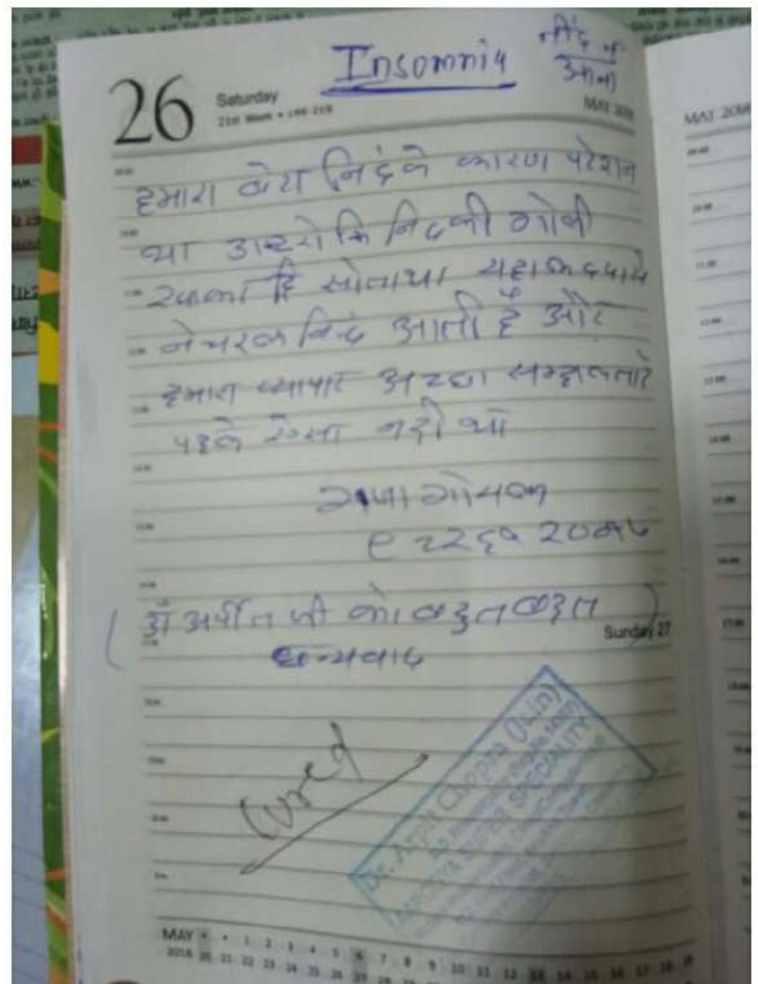
Persistent problems falling and staying asleep.

Very common

More than 10 million cases per year (India)

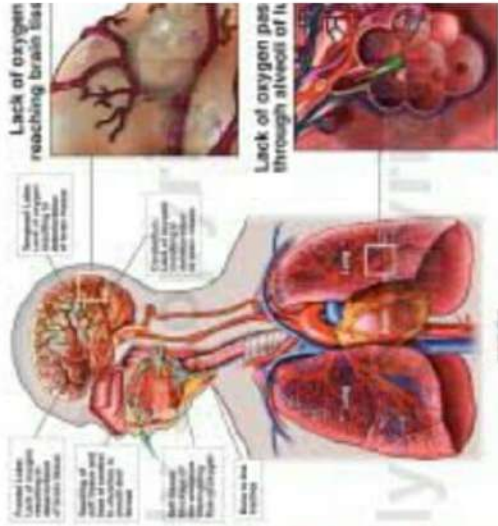
 Treatment can help, but this condition can't be cured

 Usually self-diagnosable

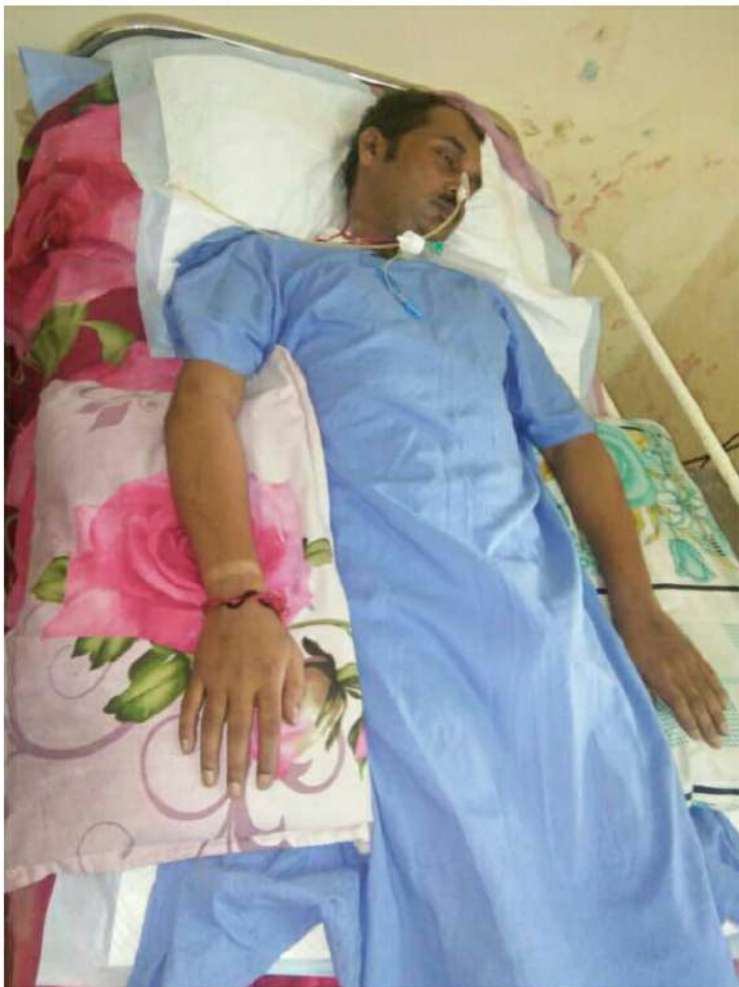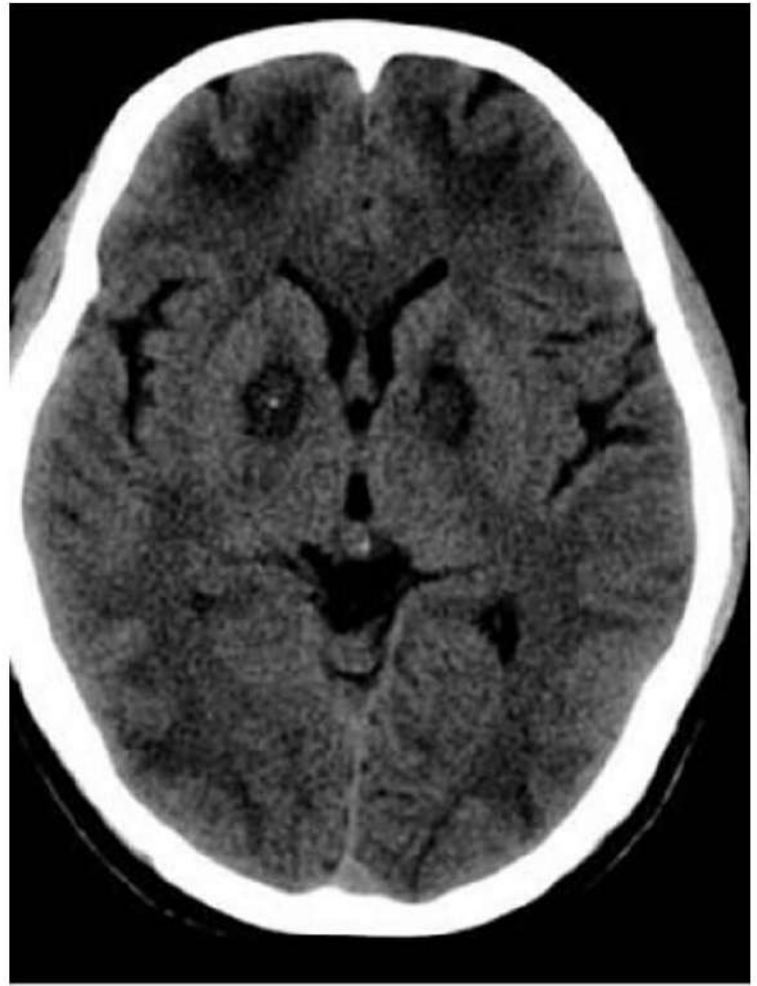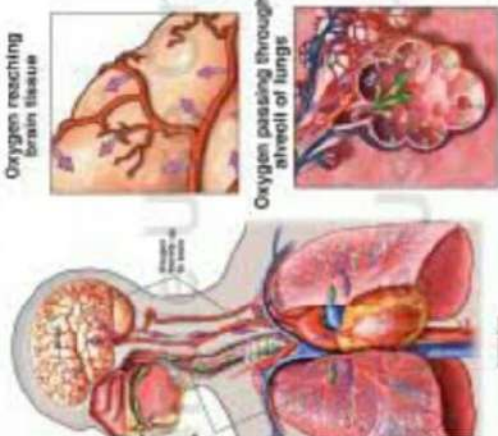


Hypoxic/Anoxic Brain Injury

Subsequent condition with blockage of airway and loss of oxygen to the brain causing slow strangulation



Normal condition with oxygen reaching the brain



Patient Name: SURUL JAISWAL 42Y/M
 Age: 42 YEARS
 Gender: M
 Image Count: 508
 Arrival Time: 22 D4 hrs
 MR Number: 6163
 Location: APOLLO RAJASHREE HOSPITAL PVT LTD INDORE (M.P.)
 Physician: DR. K. R. RAO
 Date of Exam: 20-Apr-2018
 Date of Report: 21-Apr-2018

MRI REPORT - BRAIN

TECHNIQUE: Departmental

OBSERVATION:

- Few tiny illdefined hyperintensities seen in bilateral fronto parietal occipital region - likely small vessel ischemia / ? significance.
- No evidence of acute infarct, hemorrhage or space occupying mass lesion noted.
- No evidence of abnormal signal intensity or volume loss in the hippocampi.
- The thalami, basal ganglia and internal capsules are normal on both sides.
- The ventricles and sulci are normal for the age.
- The pituitary gland, infundibulum and hypothalamus are normal for the age.
- The posterior fossa shows normal cerebellum.
- The medulla, pons and mid brain shows normal signals in all the sequences.
- Both CP angles are clear. The basal cisterns are normal.
- Normal flow void is seen in the major dural venous sinuses and arteries.

Pan sinusitis.

IMPRESSION:

- Few tiny illdefined hyperintensities seen in bilateral fronto parietal occipital region - likely small vessel ischemia / ? significance.

Pan sinusitis.

- For clinical correlation.

21 Saturday
29th Week • 203-143
JULY 2018

(Epilepsy) (मिर्गी)

I Shweti Verma, 18 yrs. old was diagnosed with epilepsy 2 years ago. Had severe headache I had to take medicine from Dr. Arpit for one month. After one month when again I underwent EEG test, now my reports came absolutely normal.

Surya Kumar, Puri, Vikas Thandi (U.P.)
:- 9412000095

(Cured)

Sunday 22

Dr. Arpit Chopra (Jain)
M.D. Homoeopathy (Reg. No. 14337)
AAROGYA SUPER SPECIALITY
Modern Homoeopathic Clinic (Computerized)
112, First Floor, Krishna Tower,
Durgam Chaudhary Road, Sec-13, Gurgaon

आरोग्य सुपर स्पेशियलिटी मॉडर्न होम्योपैथिक क्लिनिक (कम्प्यूटाइज्ड)

डॉ. अर्पित चोपड़ा (जैन)
M.D. HOMOEOPATHY
कंप्यूटरी रोग निदान
Reg. No. 14337

Phone: 011-4977070, 2502737
Mobile: 97130 92737, 97130 37137
79990-78894, 98075 27914-65
Website: www.aarogyasuper.com

पता: 112, प्रथम कोशिका
कृष्णा टॉवर, कल्याण चौक, गुरुग्राम के समीप
अर्पित चोपड़ा, एम.डी. होम्योपैथि, इण्डिया
सूर्य 11 से रोड, 3 वें फ्लोर, सूर्य: 3 से 10 बजे तक
वीकेंड सुअर 11 से रोड, 2 वें फ्लोर
Email: aarogyasuper@gmail.com
aarogyasuperindia@yahoo.com

Complete Day, 24h. Fast & Continuous Monitoring
Modern Homoeopathy Care with Advanced LifeCare

Name: Shweti Verma Age: 18 Sex: F Date: 17/07/18
Address: Puri, U.P.
Disease: Epilepsy
- Migraine

Plan:-
EEG after 1 month
Normal
Betta & lob
Cured

Correlated Epilepsy form
Betta & lob

आरोग्य सुपर की आधुनिक कम्प्यूटाइज्ड तकनीक से कल्याण सुपर स्पेशियलिटी क्लिनिक

VIDYA
E.E.G. CENTRE
Opposite Medical College, Gate No. 3, VIDYA GUEST HOUSE, Jhansi-284 129 (U.P.)
Phone: (0510) 2320313

ELECTROENCEPHALOGRAPH REPORT

BRIEF BACKGROUND INFORMATION

| | | | |
|--------------------------------|------------------------------------------------------------------------------|------|---------------|
| Patient's Name | Miss Shweti Verma | Date | 13.09.2016 |
| Clinical Diagnosis | Under Observation | Age | 16 years |
| Referring Consultant | Dr. N. S. Saxena PARS RD | Sex | Male / Female |
| Electrode System used | 10/20 International System | | |
| Paper speed | 30 mm / second | | |
| Medication given for recording | Nil | | |
| Patient's behaviour / State | Awake / Drowsy / Asleep (natural / drug induced) / Coma | | |
| Activation performed | Hyperstimulation, Photic stimulation, Sleep deprivation, Any other (specify) | | |

THE REPORT

An awake EEG record, consists of bilaterally symmetrical, 8-10 cps, alpha activity, not responding to the eye opening. Hyperventilation and photic stimulation did not show any effect. There are intermittent volleys of bilateral and generalised sharp waves, spikes & waves and sharp & slow waves in the record - mostly in montages (I), (IV) & (V).

Conclusion: Generalized epileptiform activity.

Professor D. N. Mishra
M.D., F.C.C.P., M.A.M.S.
Consultant Neuro-Physician
"Ganga" Medical College
Gate No. 3, Jhansi (U.P.)

PLEASE NOTE
♦ Inter-ictal EEG may be normal even in epileptic patients. ♦
♦ The report is to be interpreted in the light of overall clinical picture of the patient. ♦

MEDCARE MEDICAL CENTRE
RACE COURSE ROAD SQUARE INDORE (M.P.)

PATIENT INFORMATION

| | | | |
|-----------|-------------------|----------|-------------|
| ID | 1234 | REF. NO. | 1234 |
| NAME | MISS SHWETI VERMA | | |
| ADDRESS | | | |
| AGE | 18 Years | DATE | 11-Aug-2018 |
| DIAGNOSIS | EPILEPSY | | |

REF. BY: DR. N. S. SAXENA
REPORTED BY: DR. RAJESH SURJE NOLAN (M.D.)
TECHNICIAN: SHWETI VERMA

EEG REPORT

AWAKE EEG REPORT

This is a 16 channels EEG record, obtained using 10/20 International system of electrode placement. Longitudinal and transverse derivations were used to obtain bipolar & monopolar recording phasic stimulation & Hyperventilation test as activation procedures.

Background consists of 7-8 Hz alpha, 20-40 MCV, well modulated posteriorly predominant, eye opening responsive, symmetrical record with anterior theta. Beta was super imposed.

No paroxysmal epileptiform activity was seen.

Hyperventilation & Photic stimulation were uneventful.

IMPRESSION: NORMAL AWAKE EEG RECORD.

Correlate: Clinically.

DR. RAJESH SURJE NOLAN (M.D.)

Anshu Jais
 Anshu Jais
 Age - 32
 204 8084 + 912 333
MIGRAINE **Δ** **MIGRAINE**
 she was having migraine since 30 years. In that pain she couldn't sleep, eat.
 We came across this clinic information through Internet. we are taking treatment from Dr. Arpit since last 1.2 months & we have observed a lot of improvement in her condition.
 We are very thankful to you for giving her relief from her pain.
 Daughter of *putya prajapati*
 942086661

March 2016
 Monday
MIGRAINE
 07
 15-18 मध्य से रात में ही काफी तेज दर्द होता था समय के परभाव से हल्का हो जाता था।
 19-20 मध्य रात में दर्द होता था।
 21-22 मध्य रात में दर्द होता था।
 23-24 मध्य रात में दर्द होता था।
 25-26 मध्य रात में दर्द होता था।
 27-28 मध्य रात में दर्द होता था।
 29-30 मध्य रात में दर्द होता था।
 31 मध्य रात में दर्द होता था।
 Dr. Arpit Chandra (Jain)
 ALLEGRA SUPER SPECIALITY CLINIC

Dr. Arpit Chandra (Jain)
 24
 WEDNESDAY
 Two Treatment Sessions
 03
 WEDNESDAY
 Two Treatment Sessions
 03
 WEDNESDAY
 Two Treatment Sessions

Dr. Arpit Chandra (Jain)
 24
 WEDNESDAY
 Two Treatment Sessions
 03
 WEDNESDAY
 Two Treatment Sessions
 03
 WEDNESDAY
 Two Treatment Sessions

Dr. Arpit Chandra (Jain)
 24
 WEDNESDAY
 Two Treatment Sessions
 03
 WEDNESDAY
 Two Treatment Sessions
 03
 WEDNESDAY
 Two Treatment Sessions

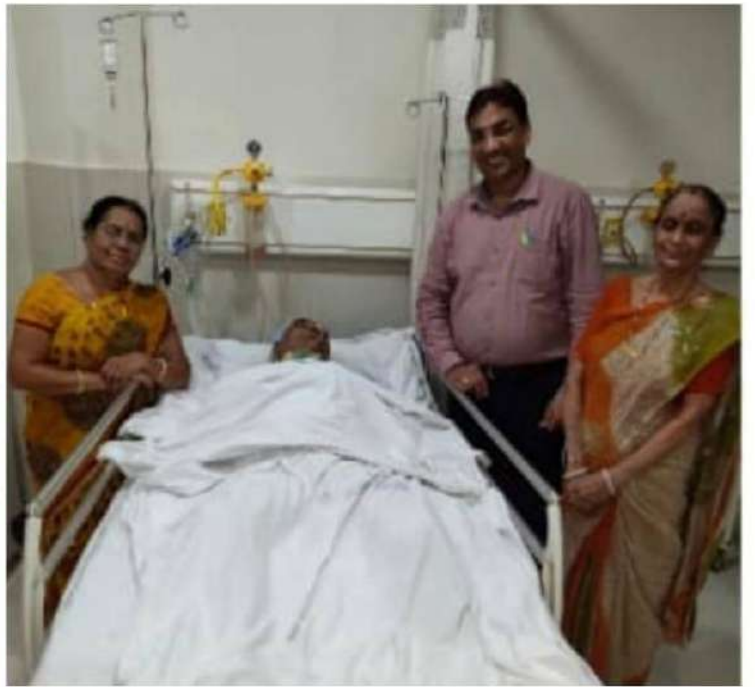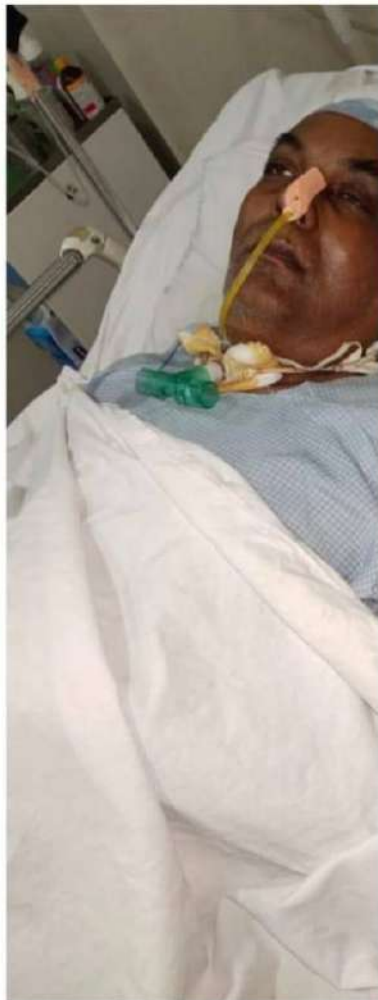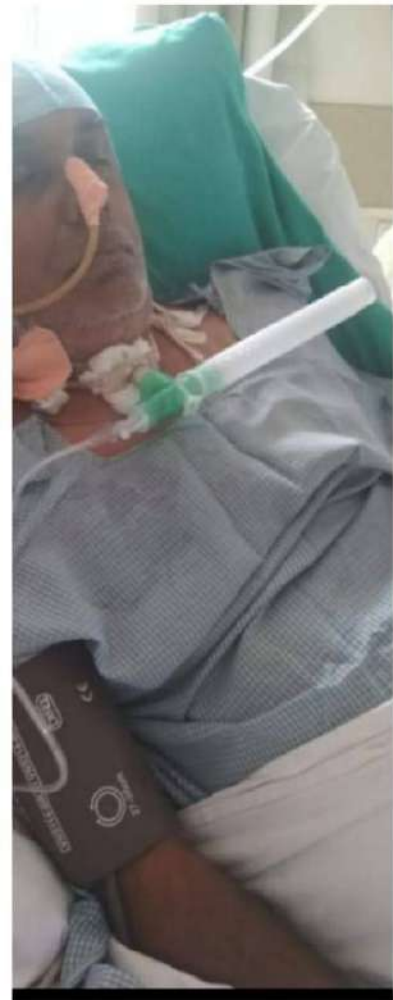Dr. Arpit Chandra (Jain)
 24
 WEDNESDAY
 Two Treatment Sessions
 03
 WEDNESDAY
 Two Treatment Sessions
 03
 WEDNESDAY
 Two Treatment Sessions



Dr. Arpit Chandra (Jain)
 24
 WEDNESDAY
 Two Treatment Sessions
 03
 WEDNESDAY
 Two Treatment Sessions
 03
 WEDNESDAY
 Two Treatment Sessions

Headache -or- Migraine

- Pain around forehead
- Mild, dull pressure
- Pain on sides of head
- Intense, pulsing, or throbbing
- Incidental, non-recurring
- Typically short-lived
- Can last for DAYS
- Nausea and dizziness
- Eye pain



2210 9122 2 A01TA1229

9 JUNE
TUESDAY

Two Thousand Nineteen

डॉ. अरुण चोपड़ा जी तारीख 14-6-19 को
को इस होगी क्योंकि जब मे अरुण
पारुण आया था तब मैंने दे रिपु रुक
नहीं था और जो पारुण वो यह लखार
कम नहीं है।

राहुल गु

COMA (HAEMORRHAGE)

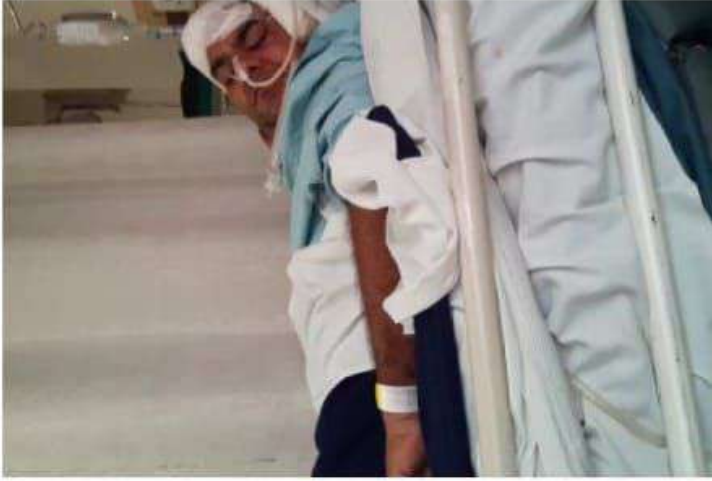24 MONDAY JUNE 19
Two Thousand Nineteen 22-6-19

मेरा माम राहुल गुप्ता है मैंने पापा को
हार्ड जेटक आया था 14-6-19 को उसी के
इलाज के दौरान ब्रेन हेमरेज हो गया सिस्डी
कजह में अरुण हाथ के तमझ कि दिमाग
कि तसे भरान हो गई थी सिस्डेलिकल
डिक्ली रे माफ मग कर दिया था अरुण
होने को 19-6-19 को मे डॉ अरुण मर
के धारु आया ~~होने~~ इनको सारी पेशेगी
लगाई कि एरुने जो इकाई आलु करवाई
उसकी वजह से 2 दिन में BP कि तिब
बना चल रही थी वो नोट हो गई और
BP नोस्टक हो गया और 4-5 दिन में
सिमाग डि मग से जो लोकेन को वो
नी कद

DR. ARPIT CHOPRA JAIN
M.D. HOMOEOPATHIC (CRITICAL & SURGICAL SPECIALIST)
INVENTOR OF: SUPER MODERN HOMEOPATHY

AAROGYA SUPERSPECIALITY MODERN HOMEOPATHY
Complete, Safe, Fast & Cost-Effective Permanent Modern Homeopathy Cure with
SPECIALIST Homeopathy Phone : 0731-4977076, Mobile : 97130-92737, 97130-37737, 79999-788

Under Weight, Hair Fall, Baldness, Warts, Deaddiction, Acidity



Dr. Arpit Chopra (Jain)
M.D. HOMOEOPATHY
(Clinical & Surgical Diseases Specialist)

997232914
9713892717

AAROGYA SUPER SPECIALITY MODERN HOMOEOPATHY

Complete, Easy, Safe, Fast & Cost-effective
Permanent Modern Homoeopathy Cure With Advance Liked
102, First Floor, Krishna Tower in front of Curwell Hoop
Jankar Vada Churaha, INDORE (M.P.)
Time : 10 am to 3pm & 5 pm to 10 pm, Sunday : 12.00 am to 2
Please Take Appointment Before Consultancy as Possible. Ph: 907
www.homoeopathyjour.rr | Email - arpit.chopra@arogya.com

997232914

Hemorrhagic stroke
Also called cerebral hemorrhage

Common
More than 1 million cases per year (worldwide)

Stroke
Also called CVA, cerebrovascular accident

Common
More than 1 million cases per year (worldwide)

Damage to the brain from interruption of its blood supply.

A stroke is a medical emergency

Requires a medical diagnosis

Lab tests or imaging always required

Treatment can help, but this condition can't be cured

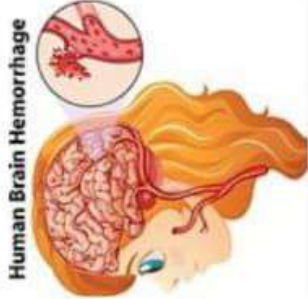
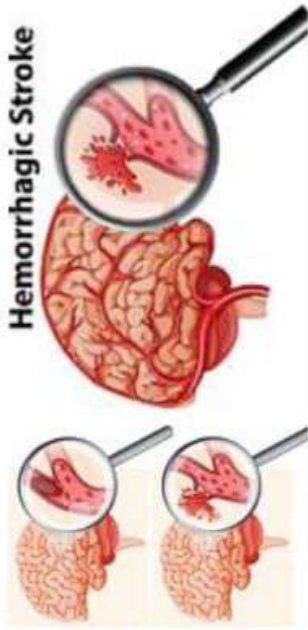
Critical needs emergency care

श्रीमान श्रीमान जीन
फोन : 997232914

मेरे Husband Mr. Pawan जीन
जानकी रम जीन के 30 जनवरी
को जीन शरीर का भाग कि
महाराष्ट्र Hospital में चलना कि
हमें भी लेना कि मैंने भी शरीर
हसा है जिसे कि दिल को काठान
शरीर की शरीर निकाला गया। एक
शरीर की शरीर हुई। 15 दिन
को जीन से रखा गया।
एक वाक हमने Dr. Arpit जीन
के सलाह मारना कि जीन व शरीर
का शरीर से शरीर शरीर शरीर
का शरीर की शरीर कि शरीर
का शरीर जीन एक शरीर ही
मैंने भी शरीर शरीर शरीर का
शरीर है। आप वाक शरीर का
शरीर शरीर है। आप कि शरीर
शरीर ही शरीर है। शरीर शरीर
शरीर शरीर शरीर शरीर
Thank you so much

Garmi Kshra Jain
9/14/2020

Hemorrhagic Stroke



Hemorrhagic stroke

Also called: cerebral hemorrhage

OVERVIEW SYMPTOMS TREATMENTS NEWS

An emergency condition in which a ruptured blood vessel causes bleeding inside the brain.

High blood pressure and trauma are two leading causes. Taking blood-thinning drugs may also increase a person's risk.

Common

More than 1 million cases per year (India)

- Treatment can help, but this condition can't be cured
- Requires a medical diagnosis
- Lab tests or imaging always required
- ▲ Critical: needs emergency care

Stroke

Also called: CVA, cerebrovascular accident

OVERVIEW SYMPTOMS TREATMENTS NEWS

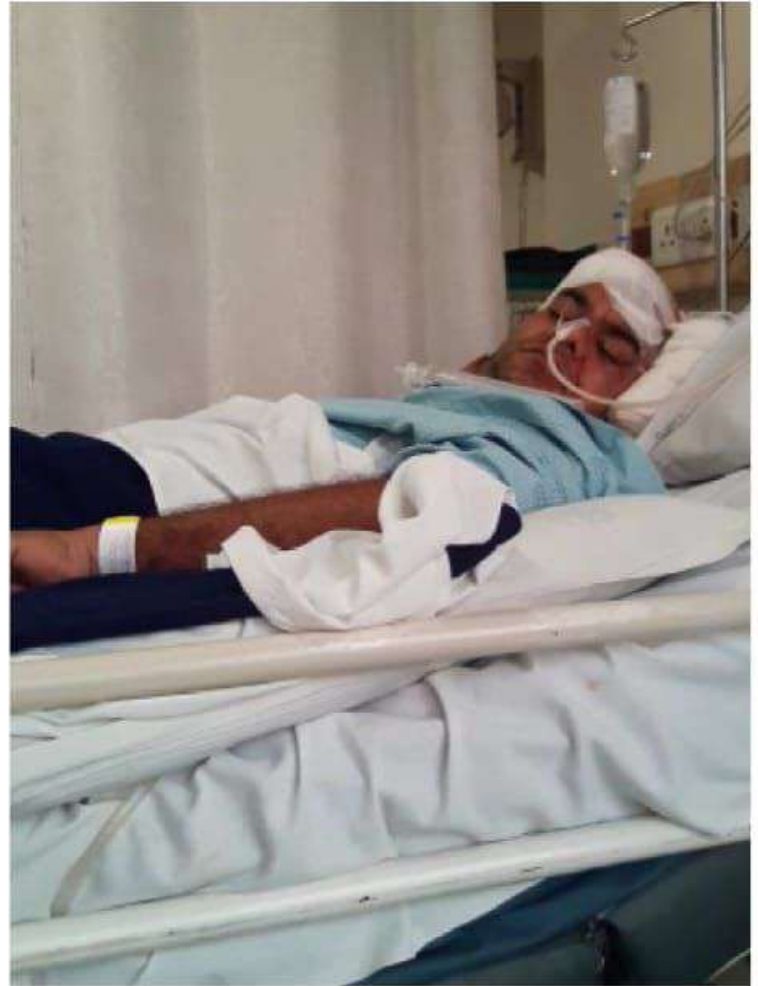Damage to the brain from interruption of its blood supply.

A stroke is a medical emergency.

Common

More than 1 million cases per year (India)

- Requires a medical diagnosis
- Lab tests or imaging always required
- Treatment can help, but this condition can't be cured
- ▲ Critical: needs emergency care



नाम : वन जैन
फोन : 9826470035

मेरे Husband Mr. Pawan जैन
जिनकी उम्र 71 वर्ष है की 20 जनवरी
2020 को ब्रेन स्ट्रोक आया था
एम्बुलेंस में ले जाया कि
उन्हें सैलेमिक नर्व में हार्टब्र
हूडा है जिसकी इल से हार्टब्र
सर्विसन फर्के निकाला गया। एक
फ्लोटी शी सर्जरी हुई। 15 दिन
तक ICU में रखा गया।
इसके बाद हमने Dr. Arpit Jain
से consultation किया व उनकी
व्याख्या से रेफरली सुधार हो
गया। अभी भी वह Dr. Arpit
Jain की व्याख्या ले रहे है।
डॉ अर्पित जैन एक बहुत ही
friendly Patient और dedicated
डॉक्टर है। आप अपने मरीजों का
बहुत ध्यान रखते है। आपके ट्रीटमेंट
बहुत ही कारगर है। इसी तरह सभी
की स्वास्थ्य लाभ प्रदान करें।
Thank you so much
Sami ksha Jain
9/4/2020



Dr. Arpit Chopra (Jain)

M.D. HOMOEOPATHY

(Critical & Surgical Diseases Specialist)



9907527914, 9713037
9713092737, 7999978

AAROGYA SUPER SPECIALITY MODERN HOMOEOPATHIC CLIN

Complete, Easy, Safe, Fast & Costeffective
Permanent Modern Homoeopathy Cure With Advance Lifestyle
102, First Floor Krishna Tower in front of Curewell Hospital
Janjeer Wala Churaha, INDORE (M.P.)

Time : 10 am to 3pm & 5 pm to 10 pm, Sunday : 12.00 am to 2.00 pm
Please Take Appointment Before Consultancy as Possible, Ph.: 0731-4977
www.homoeopathy cure.in, Email - arpitchopra23@gmail.com

aarogyahomoeopathyindore.com

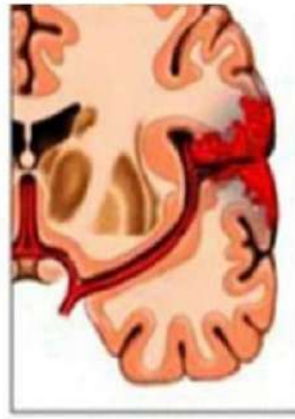
Stroke

Also called: CVA, cerebrovascular accident

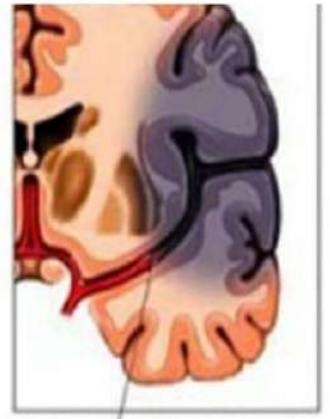OVERVIEW SYMPTOMS TREATMENTS NEWS

Damage to the brain from interruption of its blood supply.

A stroke is a medical emergency.



Hemorrhage/blood leaks into brain tissue



Clot stops blood supply to an area of the brain



rsnaa AGNOSTICS
LET'S DO GOOD.

| | |
|------------------------------------|----------------------------------------|
| PATIENT ID: MYH200200081542 | PATIENT NAME: MR. VIJAY SINGH KUSHWAHA |
| AGE: 25 YEARS | SEX: M |
| ACCESSION NUMBER: | MODALITY: MRI |
| REFERRING PHYSICIAN: DR. AMIT VYAS | STUDY: MRI BRAIN WITH ANGIO |
| STUDY DATE: 26-02-2020 | INSTITUTION NAME: MP-MYH-INDORE |

MRI - BRAIN WITH ANGIO

Technique:
Axial FLAIR, 3D SWI and diffusion. Sag T1. Coronal T2. 3D TOF for neck angiogram & circle of Willis.

Imaging features:
The brain parenchyma including bilateral basal ganglia & thalami are showing normal signals and morphology.

The brain stem and cerebellum appear normal.

There is no acute infarct on diffusion-weighted images.

No evidence of intra cranial hemorrhage / mass lesion.

The ventricles, cisterns and sulci appear normal. There is no midline shift.

MRA Brain:
MRA of circle of Willis shows normal caliber of MCAs, ACAs, PCAs, ICAs and basilar arteries.

MRA Neck:
Hypoplastic right vertebral artery.

The neck angiogram shows normal caliber and course of CCAs, ICAs and left vertebral.

Impression:

- There is no significant brain parenchymal abnormality.
- No significant stenosis or abnormal dilatation seen in circle of Willis and neck angiogram.
- Hypoplastic right vertebral artery.

Dr. D. G.
Dr. Deependra Solanki
MD Radio-diagnosis
Ex SR AIIMS New Delhi
Investigations have their limitations. Solitary pathological/radiological and other investigations never confirm the final diagnosis. They only help in diagnosing the disease in correlation to clinical symptoms and other related tests. Please interpret accordingly.

Krsnaa Diagnostics Pvt. Ltd.
Maharaja Yashwantrao Holkar (M.Y.) Hospital
Jaora Compound, Indore, Madhya Pradesh - 452 001
9907527914, 9713092737

आरोग्य सुपर स्पेशलिटी मॉडर्न होम्योपैथिक क्लिनिक

अर्पित चोपड़ा (जैन)
HOMOEOPATHY

फोन : 102, प्रथम मंजिल
कृष्णा टॉवर, रामचंद्रलाल हॉस्पिटल के सामने
जंजीरवाला बौराहा, न्यू फ्लॉरिसा, इन्दौर

सुबह : 10 से दोप, 3 बजे तक, शाम : 5 से 10 बजे तक
रात : 12 से दोप, 3 बजे तक

Email : arpitchopra23@gmail.com
aarogyamodernhomoeopathy@gmail.com

आरोग्य
COMPLETE CURE. EASY SAFE. FAST & COST EFFECTIVE.
HOMOEOPATHY

Phone : 0731-4977076
Mobile : 97130-92737, 97130-37737
99999-78894, 99075-27914
Website : www.homoeopathy cure.com / in
www.aarogyahomoeopathyindore.com

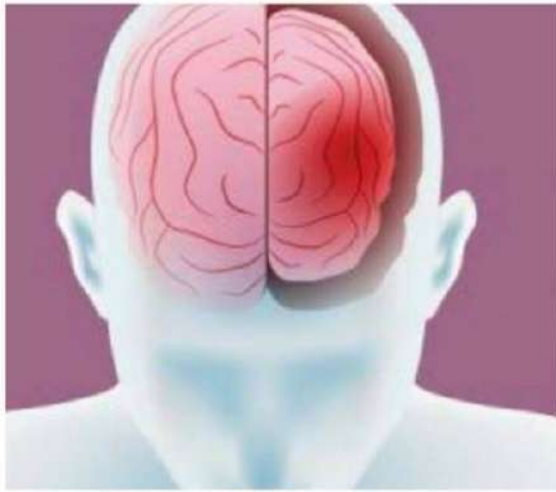Name: Vijay Singh Kushwah
Age: 25 Sex: M Date: 26/2/20
Address: Indore Mob: 9691315237
Ref No: No. 08/1/20

र. (सर्भी प्रकार एच अवरथा)
इन्डी फेसियर, अस्पताल में गर्भीर
। से गर्भी मरिठा का उन्चार, कोमा,
सिम अवस्था रोग, अँटी इन्सूलिन रोग,
ब्या थिक्लिन्सा योथ रोग, सेरिब्रल प्लूजकी,
स्कुलर डिस्टोकी, पाकिन्सन रोग,
पिन्सिपल डिस्टोकी, पाकिन्सन रोग,

Rt. side Paralysis. Smooth
on face

Dr. Arpit Chopra (Jain)
M.D. HOMOEOPATHY
(Critical & Surgical Diseases Specialist)

9907527914, 9713037
9713092737, 7999978



KNEURO POLYTRAUMA HOSPITAL
 Plot No. 10, 11, 12, 13, 14, 15, 16, 17, 18, 19, 20, 21, 22, 23, 24, 25, 26, 27, 28, 29, 30, 31, 32, 33, 34, 35, 36, 37, 38, 39, 40, 41, 42, 43, 44, 45, 46, 47, 48, 49, 50, 51, 52, 53, 54, 55, 56, 57, 58, 59, 60, 61, 62, 63, 64, 65, 66, 67, 68, 69, 70, 71, 72, 73, 74, 75, 76, 77, 78, 79, 80, 81, 82, 83, 84, 85, 86, 87, 88, 89, 90, 91, 92, 93, 94, 95, 96, 97, 98, 99, 100, 101, 102, 103, 104, 105, 106, 107, 108, 109, 110, 111, 112, 113, 114, 115, 116, 117, 118, 119, 120, 121, 122, 123, 124, 125, 126, 127, 128, 129, 130, 131, 132, 133, 134, 135, 136, 137, 138, 139, 140, 141, 142, 143, 144, 145, 146, 147, 148, 149, 150, 151, 152, 153, 154, 155, 156, 157, 158, 159, 160, 161, 162, 163, 164, 165, 166, 167, 168, 169, 170, 171, 172, 173, 174, 175, 176, 177, 178, 179, 180, 181, 182, 183, 184, 185, 186, 187, 188, 189, 190, 191, 192, 193, 194, 195, 196, 197, 198, 199, 200, 201, 202, 203, 204, 205, 206, 207, 208, 209, 210, 211, 212, 213, 214, 215, 216, 217, 218, 219, 220, 221, 222, 223, 224, 225, 226, 227, 228, 229, 230, 231, 232, 233, 234, 235, 236, 237, 238, 239, 240, 241, 242, 243, 244, 245, 246, 247, 248, 249, 250, 251, 252, 253, 254, 255, 256, 257, 258, 259, 260, 261, 262, 263, 264, 265, 266, 267, 268, 269, 270, 271, 272, 273, 274, 275, 276, 277, 278, 279, 280, 281, 282, 283, 284, 285, 286, 287, 288, 289, 290, 291, 292, 293, 294, 295, 296, 297, 298, 299, 300, 301, 302, 303, 304, 305, 306, 307, 308, 309, 310, 311, 312, 313, 314, 315, 316, 317, 318, 319, 320, 321, 322, 323, 324, 325, 326, 327, 328, 329, 330, 331, 332, 333, 334, 335, 336, 337, 338, 339, 340, 341, 342, 343, 344, 345, 346, 347, 348, 349, 350, 351, 352, 353, 354, 355, 356, 357, 358, 359, 360, 361, 362, 363, 364, 365, 366, 367, 368, 369, 370, 371, 372, 373, 374, 375, 376, 377, 378, 379, 380, 381, 382, 383, 384, 385, 386, 387, 388, 389, 390, 391, 392, 393, 394, 395, 396, 397, 398, 399, 400, 401, 402, 403, 404, 405, 406, 407, 408, 409, 410, 411, 412, 413, 414, 415, 416, 417, 418, 419, 420, 421, 422, 423, 424, 425, 426, 427, 428, 429, 430, 431, 432, 433, 434, 435, 436, 437, 438, 439, 440, 441, 442, 443, 444, 445, 446, 447, 448, 449, 450, 451, 452, 453, 454, 455, 456, 457, 458, 459, 460, 461, 462, 463, 464, 465, 466, 467, 468, 469, 470, 471, 472, 473, 474, 475, 476, 477, 478, 479, 480, 481, 482, 483, 484, 485, 486, 487, 488, 489, 490, 491, 492, 493, 494, 495, 496, 497, 498, 499, 500, 501, 502, 503, 504, 505, 506, 507, 508, 509, 510, 511, 512, 513, 514, 515, 516, 517, 518, 519, 520, 521, 522, 523, 524, 525, 526, 527, 528, 529, 530, 531, 532, 533, 534, 535, 536, 537, 538, 539, 540, 541, 542, 543, 544, 545, 546, 547, 548, 549, 550, 551, 552, 553, 554, 555, 556, 557, 558, 559, 560, 561, 562, 563, 564, 565, 566, 567, 568, 569, 570, 571, 572, 573, 574, 575, 576, 577, 578, 579, 580, 581, 582, 583, 584, 585, 586, 587, 588, 589, 590, 591, 592, 593, 594, 595, 596, 597, 598, 599, 600, 601, 602, 603, 604, 605, 606, 607, 608, 609, 610, 611, 612, 613, 614, 615, 616, 617, 618, 619, 620, 621, 622, 623, 624, 625, 626, 627, 628, 629, 630, 631, 632, 633, 634, 635, 636, 637, 638, 639, 640, 641, 642, 643, 644, 645, 646, 647, 648, 649, 650, 651, 652, 653, 654, 655, 656, 657, 658, 659, 660, 661, 662, 663, 664, 665, 666, 667, 668, 669, 670, 671, 672, 673, 674, 675, 676, 677, 678, 679, 680, 681, 682, 683, 684, 685, 686, 687, 688, 689, 690, 691, 692, 693, 694, 695, 696, 697, 698, 699, 700, 701, 702, 703, 704, 705, 706, 707, 708, 709, 710, 711, 712, 713, 714, 715, 716, 717, 718, 719, 720, 721, 722, 723, 724, 725, 726, 727, 728, 729, 730, 731, 732, 733, 734, 735, 736, 737, 738, 739, 740, 741, 742, 743, 744, 745, 746, 747, 748, 749, 750, 751, 752, 753, 754, 755, 756, 757, 758, 759, 760, 761, 762, 763, 764, 765, 766, 767, 768, 769, 770, 771, 772, 773, 774, 775, 776, 777, 778, 779, 780, 781, 782, 783, 784, 785, 786, 787, 788, 789, 790, 791, 792, 793, 794, 795, 796, 797, 798, 799, 800, 801, 802, 803, 804, 805, 806, 807, 808, 809, 810, 811, 812, 813, 814, 815, 816, 817, 818, 819, 820, 821, 822, 823, 824, 825, 826, 827, 828, 829, 830, 831, 832, 833, 834, 835, 836, 837, 838, 839, 840, 841, 842, 843, 844, 845, 846, 847, 848, 849, 850, 851, 852, 853, 854, 855, 856, 857, 858, 859, 860, 861, 862, 863, 864, 865, 866, 867, 868, 869, 870, 871, 872, 873, 874, 875, 876, 877, 878, 879, 880, 881, 882, 883, 884, 885, 886, 887, 888, 889, 890, 891, 892, 893, 894, 895, 896, 897, 898, 899, 900, 901, 902, 903, 904, 905, 906, 907, 908, 909, 910, 911, 912, 913, 914, 915, 916, 917, 918, 919, 920, 921, 922, 923, 924, 925, 926, 927, 928, 929, 930, 931, 932, 933, 934, 935, 936, 937, 938, 939, 940, 941, 942, 943, 944, 945, 946, 947, 948, 949, 950, 951, 952, 953, 954, 955, 956, 957, 958, 959, 960, 961, 962, 963, 964, 965, 966, 967, 968, 969, 970, 971, 972, 973, 974, 975, 976, 977, 978, 979, 980, 981, 982, 983, 984, 985, 986, 987, 988, 989, 990, 991, 992, 993, 994, 995, 996, 997, 998, 999, 1000.

SAI KRISHNA SUPERSPECIALITY NEURO HOSPITAL
 STATION ROAD, KACHIGUDA, HYDERABAD-500027, PH: (040)-44778599

EEG Report

| | | | |
|----------------|------------|-------------|--------|
| Patient Name: | Sai Anita | Phone No: | 9804 |
| Hospital ID: | 40472 | Sex: | Female |
| Age: | 19 Years | Height: | |
| Diagnosis: | | Technician: | |
| Ref Physician: | P.G. Babji | | |

Technical Details:
 The EEG was recorded using 10-20 international system of scalp electrode placement with minimal technical requirements. MV and Photo Stimulation were used as activation procedures.

Description:

IMPRESSION: Epileptiform activity seen.

SODANI DIAGNOSTIC CLINIC
 102, U.S. 1, Bopal Centre, Opp. Bopal Bus Stop, 102, Rao Canna Road, Indore (M.P.) & 0731-6544201

Patient's Name: **Sai Anita Chopra**

MRI Brain

Technique:
 Routine sequences were acquired in multiple planes, to evaluate the brain.

Imaging Findings:-
 The brain parenchyma and ventricular systems appear normal.
 No focal structural lesion has been identified.
 No acute lesion or restricted diffusion is seen.
 No haemorrhage, edema, mass effect or midline shift is seen.
 Brain stem & cerebellum appear normal.
 The sella, parasellar structure & CVJ appear normal.
 Visualized paranasal sinuses and mastoid air cells appear unremarkable.

Remarks:
 No significant abnormality detected on this study of the brain. No acute lesion is seen.

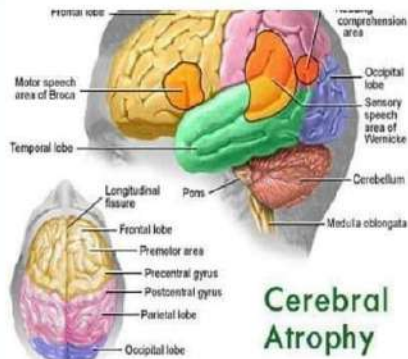
DR. BHARAT JAIN
 M.D. (Radio Diagnosis)
 Fellowship in Diagnostic Neuro-radiology (KEM, Mumbai)
 Consultant Radiologist (CT & MRI)

SODANI DIAGNOSTIC CLINIC
 102, U.S. 1, Bopal Centre, Opp. Bopal Bus Stop, 102, Rao Canna Road, Indore (M.P.) & 0731-6544201

Patient's Name: **Ms. Anita Chopra**

EEG PROTOCOL
 This is a 32-channel EEG record obtained using 10-20 International system of electrode placements. Photo stimulation & hyperventilation were used as activation procedures.

EEG REPORT
 No epileptiform activity seen.
 Found within normal limits for age.



Cerebral Atrophy

There is no specific treatment or cure for cerebral atrophy. Some symptoms of underlying causes can be managed and treated. Controlling blood pressure and eating a healthy, balanced diet is advised. Some research suggests that physical exercise may slow the speed

मॉडर्न होम्योपैथ्री

Arpita Nahar

Dr. Arpit Chopra (Jain)
 M.D. HOMOEOPATHY
 Complete, Safe, Fast & Cost Effective Permanent Modern Homoeopathy Cure with Advanced Lifestyle
 Phone: 9731-487976, Mobile: 97138-37737, 97138-37737, 79959-78884, 99875-27914
 Liver Cirrhosis, Fatty Liver, Post Brain Stroke Complications, Thyroid disorder, Infertility, Insop



COMPLETE CURE, EASY, SAFE, FAST & COST EFFECTIVE

MODERN

आरोग्य

ERN

HOMOEOPATHY

Dr. Arpit Chopra (Jain)
 M.D. HOMOEOPATHY
 (Critical & Surgical Diseases Specialist)

9907527914, 9713837737, 7995978884

AAROGYA SUPER SPECIALITY MODERN HOMOEOPATHIC CLINIC

Complete, Easy, Safe, Fast & Cost-effective
 Permanent Modern Homoeopathy Cure With Advanced Lifestyle
 102, First Floor Krishna Tower In front of Curewell Hospital
 Janjeer Wala Churaha, INDORE (M.P.)

Time : 10 am to 3pm & 5 pm to 10 pm, Sunday : 12.00 pm to 2.00 pm

Epilepsy

Also called: seizure disorder

- OVERVIEW
- SYMPTOMS
- TREATMENTS
- NEW

A disorder in which nerve cell activity in the brain is disturbed, causing seizures.

Epilepsy may occur as a result of a genetic disorder or an acquired brain injury, such as a trauma or stroke.

Common

More than 1 million cases per year (India)

Treatment can help, but this condition can't be cured

Juvenile myoclonic epilepsy is an epilepsy syndrome characterized by myoclonic jerks (quick jerks of the arms or legs), generalized tonic-clonic seizures (GTCSs), and sometimes, absence seizures. The seizures of juvenile myoclonic epilepsy often occur when people first awaken in the morning.

Juvenile Myoclonic Epilepsy
 Monday 21 DEC
 My daughter suffering from epilepsy from last one year. Now she is falling into
 P.N. Pandey
 982-6029932
 120, Gopur Colony Indore.
 Thanks Dr. Arpit Chopra. Same and his treatment

Dr. Arpit Chopra (Jain)
 M.D. HOMOEOPATHY
 (Critical & Surgical Diseases Specialist)

9907527914, 9713092737, 75

AAROGYA SUPER SPECIALITY MODERN HOMOEOPATHY

Complete, Easy, Safe, Fast & Costeffective
 Permanent Modern Homoeopathy Cure With Advance Lifestyle
 102, First Floor Krishna Tower In front of Curewell Hospital
 Janjeer Wala Churaha, INDORE (M.P.)
 Time : 10 am to 3pm & 5 pm to 10 pm, Sunday - 12.00 am to 2
 Please Take Appointment Before Consultancy as Possible, Ph:- 073
 www.homoeopathy cure.com, Email - arpitchopra23@gmail.com

SODANI DIAGNOSTIC CLINIC
 H/O.: L.G.-1, Morya Centre, Opp. Basket Ball Club, 16/1, Race Course Road, Indore (M.P.)
 Phone : 0731 - 4766222, 8617770150

Patient's Name : Ms. Shivani Pandey
 Age / Sex : 23 Years / FEMALE
 Referred By : Dr. Chopra Arpit Jain MD(Homeo)
 Visit Id : 1021002195
 Registration : 04/01/2021
 Reported : 05/01/2021 12:14
 Company : NA

EEG PROTOCOL

This is a 32-channel EEG record obtained using 10-20 International systems of electrode placements. Photoc stimulation & hyperventilation were used as activation procedures.

EEG REPORT

- No epileptiform activity seen.
- Record within normal limits for age.

Kindly Correlate Clinically

Medical Cannabis for Juvenile Myoclonic Epilepsy

- Confusion
- Aura
- Sudden falls
- Strang
- Uncontrollable jerking movements
- Strange sensations and emotions
- Loss of consciousness or awareness

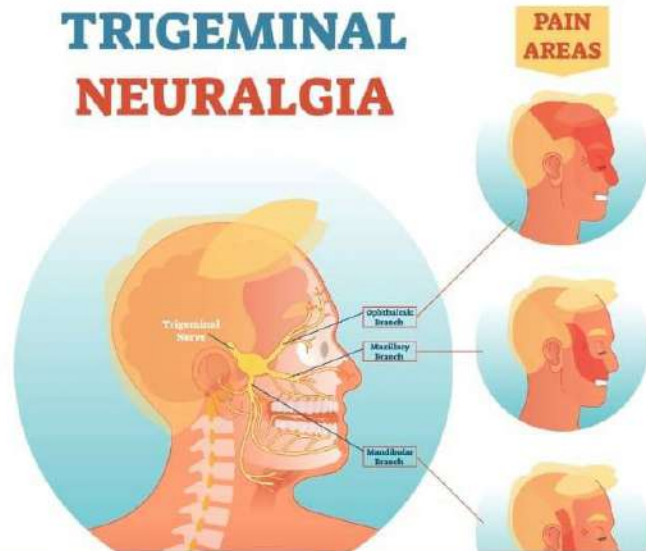
आरोग्य सुपर स्पेशलिटी मॉडर्न होम्योपैथिक क्लिनिक

कम्पलिट * परमानेन्ट * ईजी * सेफ * फास्ट एण्ड कॉस्ट इफैक्टिव

* कैंसर * किडनी फेलियर * अस्पताल में गंभीर रूप से भर्ती मरिजों का उपचार * कोमा *
 * शल्य चिकित्सा योग्य रोग * आँटो इन्यून रोग * जीवनभर दवाई लेने वाले रोगों की रोकथाम
 एवं 300 प्रकार के असाध्य जटिल रोगों की चिकित्सा ।

102, 104, प्रथम मंजिल, कृष्णा टॉवर, क्योरवेल हॉस्पिटल के सामने, जंजीरवाला चौराहा, न्यू पलासिया, इन्दौर (म.प्र.)
 फोन : 0731-4977076, मो. : 97130-92737, 97130-37737, 79999-78894, 99075-27914
 www.homoeopathy cure.in, www.aarogyahomoeopathyindore.com Email : arpitchopra23@gmail.com

TRIGEMINAL NEURALGIA



Trigeminal neuralgia

Also called: tic douloureux

Overview

Symptoms

Treatments

A chronic pain condition affecting the trigeminal nerve in the face.

The trigeminal nerve carries sensation from the face to the brain. It's most common in women aged over 50.

Rare

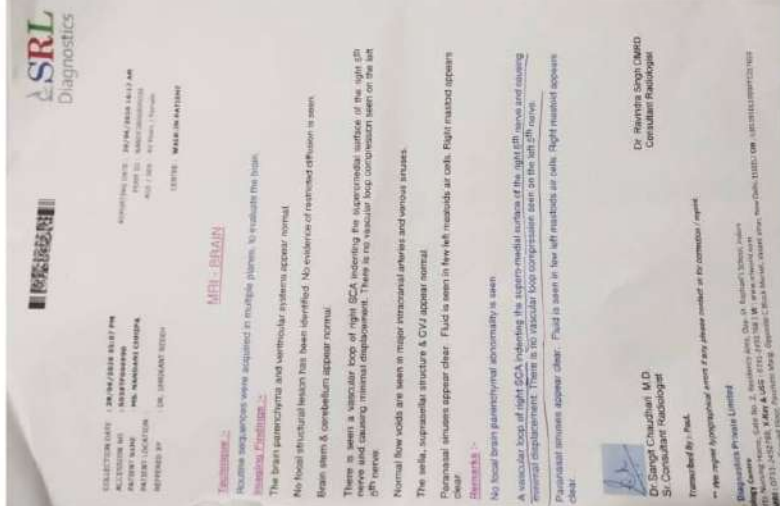
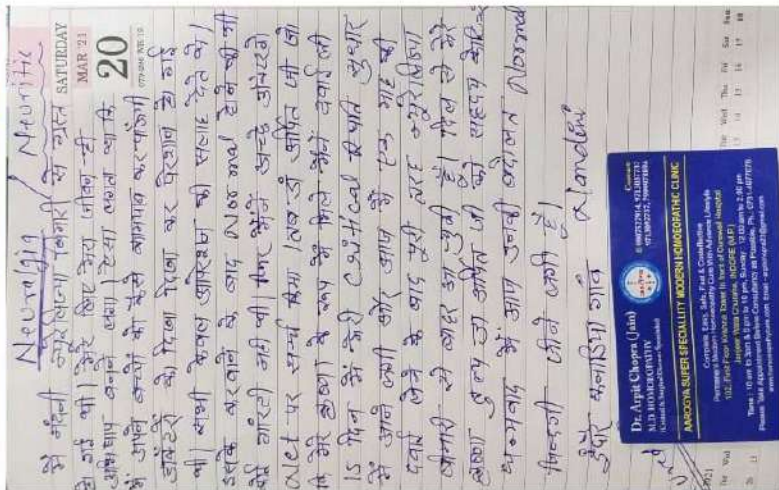
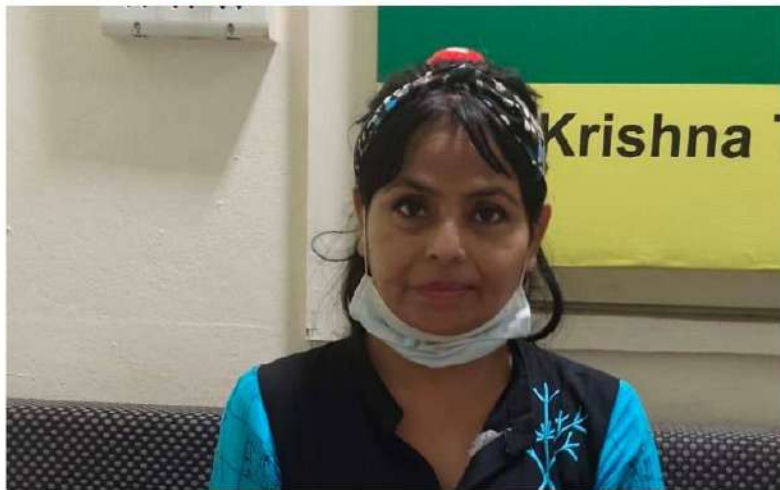Fewer than 1 million cases per year (India)

Treatment can help, but this condition can't be cured

Requires a medical diagnosis

Lab tests or imaging rarely required

Chronic: can last for years or be lifelong



आरोग्य सुपर स्पेशलिटी माडर्न हॉस्पिटल क्लिनिक

डॉ. अर्पिता चौधरी (जेन.)
एम.डी. होमोपैथी
जटिल, अस्पताल एवं
शल्य रोग विशेषज्ञ

कम्पलिट * परमानेंट * ईजी * सेफ * फास्ट एण्ड कॉस्ट इफैक्टिव

*** कैंसर * किडनी फैलियर * अस्पताल में गंभीर रूप से भर्ती मरिजों का उपचार * कोमा ***
*** शल्य चिकित्सा योग्य रोग * आँटो इम्यून रोग * जीवनभर दवाई लेने वाले रोगों की रोकथाम**
एवं 300 प्रकार के असाध्य जटिल रोगों की चिकित्सा ।

102, 104, प्रथम मंजिल, कृष्णा टॉवर, क्योरवेल हॉस्पिटल के सामने, जंजीरवाला चौराहा, न्यू पलासिया, इन्दौर (म.प्र.)
फोन : 0731-4977076, मो. : 97130-92737, 97130-37737, 79999-78894, 99075-27914

Parkinson's disease

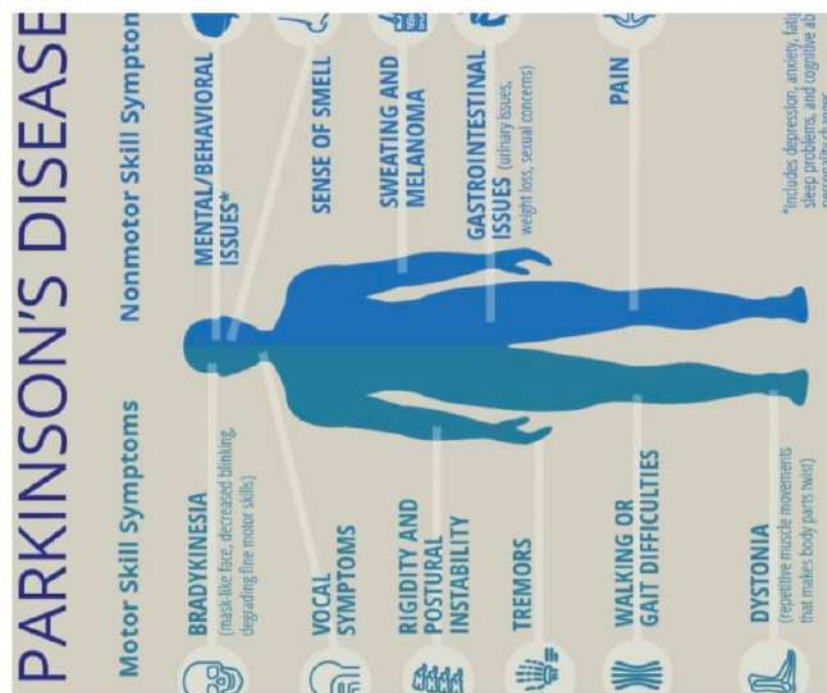
Overview

Symptoms

Treatments

A disorder of the central nervous system that affects movement, often including tremors.

Nerve cell damage in the brain causes dopamine levels to drop, leading to the symptoms of Parkinson's.




आरोग्य सुपर स्पेशलिटी
 माडर्न होम्योपैथिक क्लिनिक
Dr. Arpit Chopra (Jain)
 M.D. HOMOEOPATHY
 (CRITICAL & SURGICAL DISEASES SPECIALIST)
 9907527914, 9713092737



विशेषताएं :

कैंसर, किडनी फैलियर, अस्पताल में गंभीर रूप से भर्ती मरीजों का उपचार, कोमा, ऑटो इम्यून रोग, शल्य चिकित्सा योग्य रोग, हायपोथायराइडिज्म, एलर्जी, बालों का झड़ना, एग्जीमा, सोरायसीस, व्यसन मुक्ति, चर्म रोग, एसीडीटी, मोटापा, ल्यूकोडर्मा, माइग्रेन, गुप्तरोग, पथरी, साइनूसाइटिस, एनिमिया, लकवा, पाईल्स, गठिया, अस्थमा एवं श्वसन संबंधी रोग, होम्योपैथिक प्रतिरोधक एवं होम्योपैथी टिटनेस, नपूसंकता, मुहांसे, वंशानुगत रोग, साइटिका, डिप्रेशन मानसिक रोग, हृदय रोग, मलेरिया, मासिक रोग, ब्लड प्रेशर, डायबिटीज एवं गुर्दा, संबंधी रोग, टायफाइड, टोन्सिलाइटिस पुराने असाध्य रोग इत्यादि का त्वरित चिकित्सा ।

क्या आप पार्किंसन से परेशान हैं



Patient - Naresh Singh Besh

PARKINSON'S DISEASE



पार्किंसन को कैसे खत्म करे



15:30 Dr. Arpit Chopra Jain

Treatment Of Parkinsons By Modern Homeopathy

कैंसर, किडनी फेलियर, अस्पताल में गंभीर रूप से
भर्ती मरिजों का उपचार, कोमा, शल्य चिकित्सा योग्य रोग,
ऑटो इम्यून रोग, जीवनभर दवाई लेने वाले रोगों की रोकथाम एवं
300 प्रकार के असाध्य जटिल रोगों की चिकित्सा।



डॉ. अर्पित चौपडा (जैन)
एम. डी. होम्योपैथी
जटिल, असाध्य एवं
शल्य रोग विशेषज्ञ

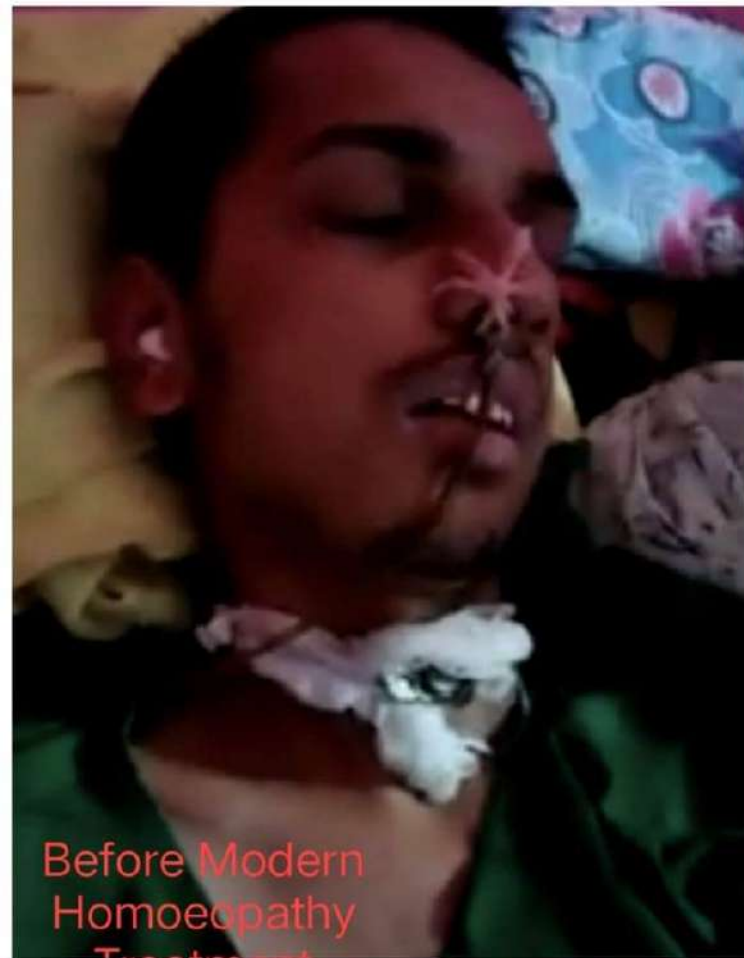
आरोग्य सुपर स्पेशलिटी मॉडर्न होमियोपैथी

कम्प्लिट, परमानेन्ट, ईजी, सेफ, फास्ट एण्ड कॉस्ट इफैक्टिव

102, प्रथम मंजिल, कृष्णा टॉवर, क्योरवेल हॉस्पिटल के सामने, जंजीरवाला चौराहा, न्यू पलासिया, इन्दौर म.प्र.

📞 99075 27914 संपर्क : 0731-4977076, 79999 78894

www.homoeopathy cure.in, www.aarogyahomoeopathyindore.com Email : arpitchopra23@gmail.com



Before Modern
Homoeopathy
Treatment



After Modern
Homoeopathy
Treatment Cured



Coma

Overview

Treatments

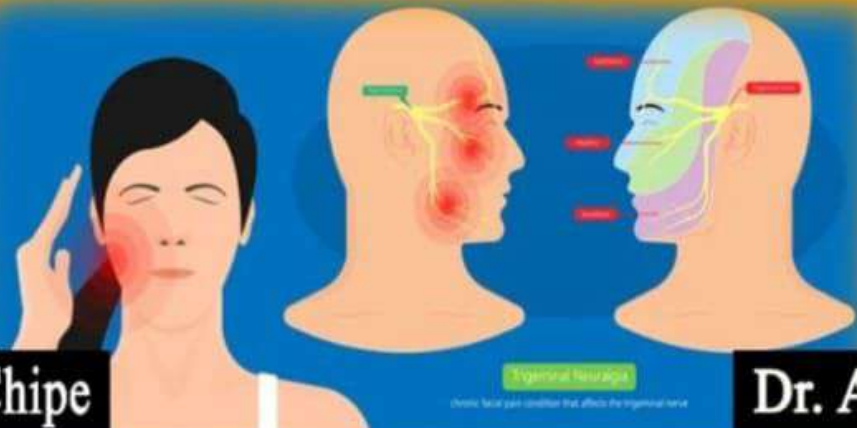
Ne

A period of prolonged unconsciousness by illness or injury.



क्या आप ट्राइजेमिनल न्यूराल्जिया से परेशान हैं

ट्राइजेमिनल न्यूराल्जिया को कैसे खत्म करें



Patient - Nandini Chipe

Dr. Arpit Chopra J

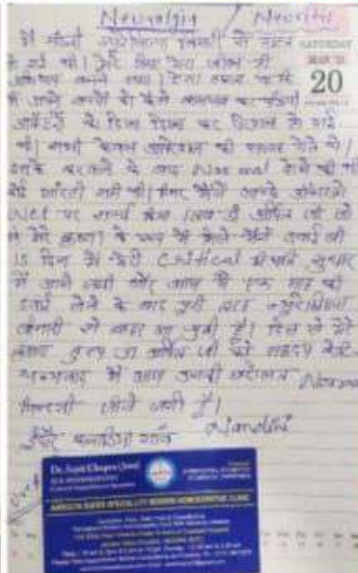
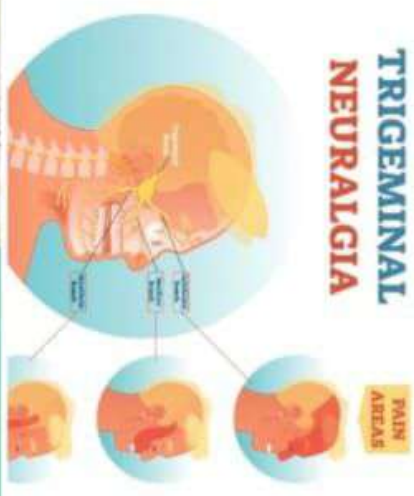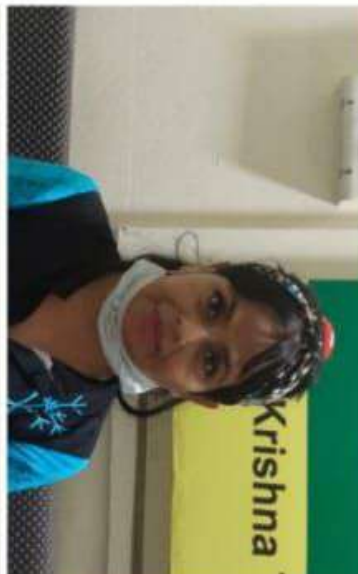Treatment Of Trigeminal Neuralgia By Modern Homeopathy

आरोग्य सुपर स्पेशलिटी माइनो हास्यापथिक क्लिनिक

कपालित * परमानेंट * इजी * सेफ * फास्ट एण्ड कॉस्ट इफैक्टिव

* कैंसर * किडनी फेलियर * अस्थिगत में गंभीर रूप से भर्ती मरीजों का उपचार * कोमा * शल्य चिकित्सा योग्य रोग * आर्टो स्क्वोर रोग * जीवनभर दवाई लेने वाले रोगों की रोकथाम एवं 300 प्रकार के असाध्य जटिल रोगों की चिकित्सा।

102, 104 प्रथम मंजिल, कृष्णा टॉवर, क्यारोवेल हाॅस्पिटल के सामने, जंजीरवाला चौराहा, न्यू परारिया, इन्डोर (म.प्र.)
फ़ोन : 0731-4977076, मो. : 97130-92737, 97130-37737, 799999-78894, 99075-27914



Trigeminal neuralgia

Also called: tic douloureux

Overview Symptoms Treatments

A chronic pain condition affecting the trigeminal nerve in the face.

The trigeminal nerve carries sensation from the face to the brain. It's most common in women aged over 50.

Rare
Fewer than 1 million cases per year (India)

- Treatment can help, but this condition can't be cured
- Requires a medical diagnosis
- Lab tests or imaging rarely required
- Chronic: can last for years or be lifelong

MIGRAINE

Permanently

12:36

Dr. Arpit Chopra

कैंसर, किडनी फेलियर, गंभीर रूप से भर्ती मरीजों कोमा, ऑटो इम्यून रोग, शोथ रोग, हायपोथायराइडिज्म, बालों का झड़ना, एंजीमा, व्यसन मुक्ति, चर्म रोग, एसीडिबिलिटी, माइग्रेन, गुर्मा साइनुसाइटिस, एनिमिया, लस गडिया, अस्थमा एवं स्वसन होम्योपैथिक प्रतिरोधक एंटीबिओटिक्स, नपुंसकता, मुहांसे, साइटिका, डिप्रेशन मानसिक समस्याएँ, मलेरिया, गार्जिक रोग, डायबिटीज एवं गुर्दा, टायफाइड, टोन्सिलाइटिस असाध्य रोग इत्यादि का त्वरित

Handwritten notes and a woman holding her head in pain.

MIGRAINE

Success Story

0:21

माइग्रेन को कैसे खत्म करें

0:21

Migraine Cured 1000% with guarantee up to 30 years old problems for Complete,

MIGRAINE

Success Story

-49

6 वर्ष पुराना

100 % सफलता

0:25

Dr. Arpit Chopra Jain
Homoeopathy & Case Specialist

MIGRAINE

June 30

Handwritten notes and a doctor's card for Dr. Arpit Chopra Jain.

माइग्रेन को कैसे खत्म करें

20:23

Patient - Kiran Sharma

क्या आप ट्राइजेमिनल न्यूराल्जिया से परेशान हैं

ट्राइजेमिनल न्यूराल्जिया को कैसे खत्म करें

Patient - Nandini Chipe

Dr. Arpit Chopra Jain

Treatment Of Trigeminal Neurologia By Modern Homeopathy

कैंसर, किडनी फेलियर, अस्पताल में गंभीर रूप से भर्ती मरीजों का उपचार, कोमा, शल्य चिकित्सा योग्य ऑटो इम्यून रोग, जीवनभर दवाई लेने वाले रोगों की रोक 300 प्रकार के असाध्य जटिल रोगों की चिकित्सा

डॉ. अर्पित चौपड़ा (जैन)
एम. बी. होम्योपैथी जटिल, असाध्य एवं शल्य रोग विशेषज्ञ

आरोग्य सुपर स्पेशलिटी माईन होमिओपैथी

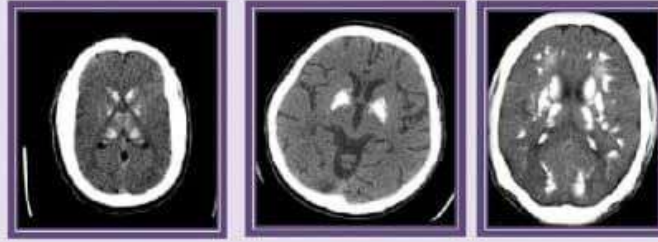
कम्पलिट, परमानेंट, ईजी, सेफ, फास्ट एण्ड कॉस्ट इफैक्टिव

102, प्रथम मंजिल, कृष्णा टॉवर, कयोरेवेल हॉस्पिटल के सामने, जंजीरवाला चौराहा, न्यू दिल्ली

99075 27914 संपर्क : 0731-4977076, 79999 78894

www.homoeopathy cure.in, www.aarogyahomoeopathyindore.com Email : arpit

Fahr disease



➤ (Also known as familial cerebral ferrocalcinosis) is a congenital disorder characterized by abnormal calcium deposition with subsequent atrophy involving the basal ganglia +/- cerebral and cerebellar cortical regions. Both autosomal dominant and auto recessive inheritance patterns have been proposed. There is variable expressivity.

➤ Clinical presentation

➤ Initially patients can be asymptomatic. Severe forms can later present with progressive psychosis, cognitive impairment, dementia, movement disorders, and parkinsonian symptoms.

➤ Radiographic features

➤ CT

➤ Shows extensive calcification bilaterally involving basal ganglial region as well as elsewhere in the brain.

मॉडर्न होम्योपैथी

DR. PANKAJ TIWARI | DR. MANOJ TIWARI

AAROGYA SUPERSPECIALITY MODERN HOMEOPATHIC CLINIC
 Kharidola, Sahyodra Road, C-10, Sector-10, Vashi, Mumbai-400 705, Maharashtra, India
 Phone: 0731-4977314, 0731-4977315, 0731-4977316, 0731-4977317, 0731-4977318, 0731-4977319

कैसर, किडनी फेलियर, अस्पताल में गंभीर रूप से भर्ती मरिजों का उपचार, कोमा, शल्य चिकित्सा योग्य रोग, ऑटो इम्यून रोग, जीवनभर दवाई लेने वाले रोगों की रोकथाम एवं 300 प्रकार के असाध्य जटिल रोगों की चिकित्सा।

आरोग्य सुपर स्पेशलिटी मॉडर्न होमियोपैथी
 कम्प्लिट, परमानेंट, ईजी, सेफ, फास्ट एण्ड कॉस्ट इफेक्टिव

102, प्रथम मंजिल, कृष्णा टॉवर, क्योरवेल हॉस्पिटल के सामने, जंजीरवाला चौराहा, न्यू पलासिया, इन्टीर म.प्र.
 96076 27914 संपर्क : 0731-4977076, 79669 78894
 www.homeopathyvare.in, www.aarogyahomeopathyindore.com, Email: arnitchopra23@gmail.com

DIAGNOSTIC REPORTS OF MR.MANOJ TIWARI(FAHR)

Four diagnostic reports from SHALBY Health Care are shown, detailing the patient's history, physical examination, and radiological findings. The reports confirm the presence of bilateral calcification in the basal ganglia, consistent with Fahr disease.

कैंसर, किडनी फेलियर, अस्पताल में गंभीर रूप से
 भर्ती मरिजों का उपचार, कोमा, शल्य चिकित्सा योग्य रोग,
 ऑटो इम्यून रोग, जीवनभर दवाई लेने वाले रोगों की रोकथाम एवं
 300 प्रकार के असाध्य जटिल रोगों की चिकित्सा।



आरोग्य सुपर स्पेशलिटी मॉडर्न होमियोपेथी

कम्पलिट, परमानेन्ट, ईजी, सेफ, फास्ट एण्ड कॉस्ट इफैक्टिव

102, प्रथम मंजिल, कृष्णा टॉवर, क्योरवेल हॉस्पिटल के सामने, जंजीरवाला चौराहा, न्यू पलासिया, इन्दौर म.प्र.

📞 99075 27914 संपर्क : 0731-4977076, 79999 78894

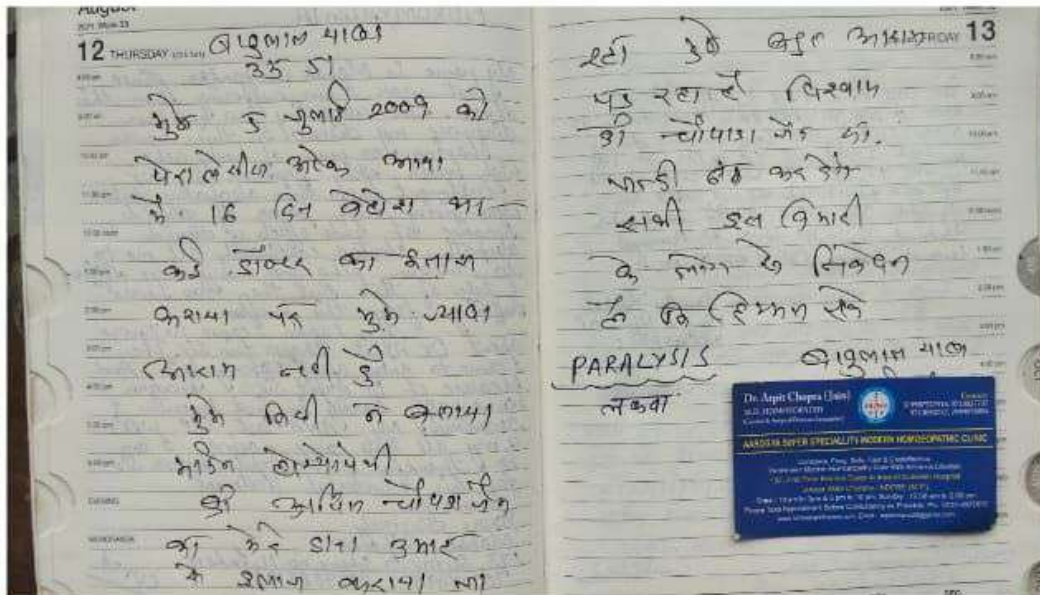
www.homoeopathy cure.in. www.aarogyahomoeopathyindore.com Email : arpitchopra23@gmail.com



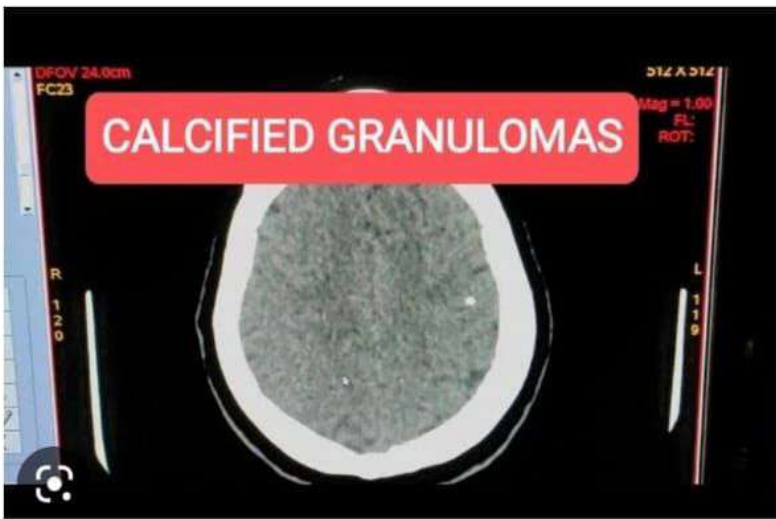🔊 इसे सुनें

पक्षाघात या लकवा मारना (Paralysis) एक या एकाधिक मांसपेशी समूह की मांसपेशियों के कार्य करने में पूर्णतः असमर्थ होने की स्थिति को कहते हैं। पक्षाघात से प्रभावी क्षेत्र की संवेदन-शक्ति समाप्त हो सकती है या उस भाग को चलना-फिरना या घुमाना असम्भव हो जाता है। यदि दुर्बलता आंशिक है तो उसे आंशिक पक्षाघात कहते हैं।

Types of Paralysis



Paralysis पक्षाघात या लकवा मारना of 13 years Pt responded by Dr Arpit Chopra Jain Modern Homeopathy



K/O Calcified Granuloma ✓
 Sub-centimetric calcified lesion ✓
 - Oedema in post. parietooccipital region ✓
 - No H/O DM II, HTN, fever ✓
 - Weak memory ⊕ (Loss) (Heard H- ✓)

Excel Diagnostics
 Whole body CT Scan, X-Ray, IVP, ECG, NCG, EMG, TMT, EEG, ECHO, VEP, Bera, Audiometry, ABG, VBG, D-Dimer, PCT, Trop T, HbA1c, Doppler (Diabetes Study)

A2 Hospital Campus, Kamla Rai College Road, Gopalganj (Bihar) 841428

Patient Name: PARMESHWAR PASWAN Patient ID: 22915
 Sex / Age: M / Report Date/Time: 08-10-2022
 Modality: CT Ref. Phys: DR ARUN KUMAR

NCCT - HEAD

SUPRATENTORIAL REGION:

- Falc calcification seen.
- Subcentimetric sized calcified lesion without any surrounding oedema noted in posterior parietooccipital region on left side - old calcified granuloma.
- Rest of the brain parenchyma normal.
- Ventricular system is normal.
- No midline shift is noted.
- Basal cisterns are normal.
- Basal ganglia, thalamus and cerebellum capsule are normally seen.

POSTERIOR FOSSA REGION:

- 4th ventricle is normal and seen in midline.
- Cerebellar hemispheres, vermis and brain stem are grossly normal.

IMPRESSION:

SUBCENTIMETRIC SIZED CALCIFIED LESION WITHOUT ANY SURROUNDING OEDEMA NOTED IN POSTERIOR PARIETOOCCIPITAL REGION ON LEFT SIDE - OLD CALCIFIED GRANULOMA.

AD - Kindly Review with clinical findings

Kapish
 DR. KAPISH MITTAL
 M.D. RADIO DIAGNOSIS

Before Treatment

SUMAN CT SCAN & IMAGING CENTRE
 (A Unit of Suman Medical Research Centre & Hospital Pvt. Ltd.)
 Call : 6202819977, 9334059131

Dr. Nehal Kumar
 MBBS, DMRD
 Consultant Radiologist

| | | | |
|---------------|-------------------|-------------|------------|
| Patient Name: | PARMESHWAR PASWAN | Patient ID: | 9950 |
| Modality: | CT | Sex: | M |
| Age: | 48Y | Study: | HEAD |
| Ref. Dr.: | ARUN KUMAR (RAMS) | Study Date: | 19-01-2023 |

Plain CT study of Brain

- Posterior fossa structures-brain stem & cerebellum are normal.
- Both gangliocapsular regions are normal.
- Supratentorial compartment does not reveal any abnormal density.
- Ventricular system, basilar cisterns are normal.
- There is no shift of midline structures.
- Visualized parts of orbit & paranasal sinuses appear normal.
- Skull vault appears normal.

Plain C.T. Study of Brain reveals no significant abnormality.

* This report is not valid for medico legal purpose

Dr. Nehal Kumar
 MBBS, DMRD
 Consultant Radiologist

After Dr Arpit Chopra Modern Homoeopathy Online Treatment

A calcified granuloma is a specific type of tissue inflammation that has become calcified over time. When something is referred to as "calcified," it means that it contains deposits of the element calcium. Calcium has a tendency to collect in tissue that is healing.



Calcified Granuloma In Brain - Had Seizures...

Visit

* कैंसर * किडनी फेलियर * अस्पताल में गंभीर रूप से * भर्ती मरिजों का उपचार * कोमा * शल्य चिकित्सा योग्य रोग आँटो इन्फ्यून रोग * जीवनभर दवाई लेने वाले रोगों की रोकथाम एवं 300 प्रकार के असाध्य जटिल रोगों की चिकित्सा ।

आरोग्य सुपर स्पेशलिटी मॉडर्न होम्योपैथिक क्लीनिक

कम्प्लिट * परमानेन्ट * ईजी * सेफ * फास्ट एण्ड कॉस्ट इफेक्टिव

102, प्रथम मंजिल, कृष्णा टॉवर, क्योरवेल हॉस्पिटल के सामने, जंजीरवाला चौराहा, न्यू पलासिया, इन्दौर (म.प्र.)
 फोन : 0731-4977076, मो. : 97130-92737, 97130-37737, 79999-78894, 99075-27914

www.homoeopathycure.in, www.aarogyahomoeopathyindore.com Email : arpitchopra23@gmail.com

डॉ. अर्पित चोपड़ा (मैन)
 एम. डी. होम्योपैथी
 जटिल, असाध्य एवं
 शल्य रोग विशेषज्ञ

COMPLETE CURE EASY SAFE, FAST & COST EFFECTIVE
 MODERN HOMOEOPATHY



MRI CENTRE, SIR GANGA RAM HOSPITAL

Rajinder Nagar, New Delhi - 110 060
Ph. : 4311 5700 - 30, 4225 1909

RADIOLOGISTS

DR. T.B.S. BUKI
M.D.
In-charge of Dept.

DR. ADITI SUD
D.N.B.

DR. SEEMA SUD
D.N.B.

| | | | |
|----------------------------|--------------|-----------------|----------------------|
| Patient Name (Last, First) | GHOSH LAVVYA | Age/Sex | 10 Months F |
| Reg. No. | 1809535 | Ward No. | MRI |
| Episode No. | OP01942558 | Exam No. | 7 |
| Imaging No. | 7087791-25 | Examined On | 30-Jul-16 09:58:21AM |
| Location | MRI | Location Type | DDP |
| Referred By | | External Doctor | |

Na
MULTIPLANAR MR IMAGING OF BRAIN WAS PERFORMED ON 3T MAGNET SYSTEM USING DEDICATED HEAD COIL IN SPIN ECHO T1W, T2W AND TIRM SEQUENCES. SECTIONS WERE TAKEN IN AXIAL, SAGITTAL AND CORONAL PLANES. IN ADDITION HIGH RESOLUTION CORONAL OBLIQUE TIRM STUDY WAS PERFORMED FOR EVALUATION OF THE HIPPOCAMPAL REGIONS.

History of pre-term during pregnancy and maternal pregnancy induced hypertension.

A focal area with encephalomalacic changes and the white matter loss is seen in right periventricular, peri-trigonal region with atrophic cortical gyri. This area shows hyperintense signal on T1W and TIRM images, and hyperintense signal on T2W images and demonstrates evidence of blooming along the gyri in the right parietal and the temporal lobe. The right occipital horn shows ex vacuo prominence. The cortex appears thickened on the right parietal and the temporal lobe in comparison to the opposite side. Bilateral thalami appear unremarkable. Brainstem also appears unremarkable. Cerebellum shows no obvious abnormality. Major vascular flow voids are maintained. Generalized atrophic changes are seen in bilateral cerebral hemispheres with prominence of CSF space.

IMPRESSION:
MR findings reveal a focal encephalomalacic area in the right periventricular peri-trigonal region with white matter loss and atrophy of the overlying cortex, and the cortex in the right temporal and the frontal lobe appear relatively thickened and with peripheral areas of blooming also seen in the right parieto-temporal lobe. Findings are consistent with old ischemic insult.

before Treatment

NOT FOR MEDICO LEGAL PURPOSES
It is a Diagnostic. Like all diagnostic modalities, MRI also has its limitations. Therefore it is a Diagnostic. Like all diagnostic modalities, MRI also has its limitations. Therefore it is a Diagnostic.

VENUS MD, CT CENTRE SHANKAR NAGAR, BHOPAL Phone: 9479360865, 9229443283

EEG & BRAIN MAP ANALYSIS

Patient No.: 3
Name: Baby Lavya Ghosh
Address: Bhopal

Date: 29-07-2023 06:59:33
Age: 8 Years (F)
Consult: Dr. Rohit Joshi

Last Med:

Last Attack:

Cooperation:

Handedness:

Medication:

The EEG Shows NORMAL Findings.

BACKGROUND ACTIVITY:

The record show background Theta activity at 4-7cps it was synchronous Low Voltage Fast Beta activity at 18-22cps was seen anteriorly on both sides.

EPISODIC ACTIVITIES:

There is no spike, sharp, spike & wave discharge anywhere in the tracing. Suppression bursts or periodic slow complexes are not seen.

PROVOCATIVE TECHNIQUES:

Photic stimulation from 3 Hz to 25 Hz with eyes shut, does not provide any epileptic activity.

BRAIN MAPPING:

Brain mapping reveals no significant asymmetry in frequency. Amplitude map is also normal.

IMPRESSION:

The Awake EEG Shows Normal Finding. There Is No Evidence Of Aoe Abnormality.

Please Correlate Clinically.

**After Dr Arpit Chopra
Jain Modern
Homoeopathy**

Dr. Rohit Joshi MD, MRCPCH CCT (ONC) FRCR
PEDIATRIC NEUROPHYSICIAN

This EEG Report Is Only Professional Report And Is Not Fit For Medicolegal Purposes.

**After Dr Arpit Chopra
Jain Modern
Homoeopathy**

Before Treatment

EPILEPSY CURED WITH NEUROCYSTIC...
Dr Arpit Chopra's SuperS...
786 views • 4 years ago

NEUROLOGICAL BRA...
Dr Arpit Chopra's SuperS...
3K views • 8 months ago

Epilepsy Treatment & cure by Dr Arpit Ch...
Dr Arpit Chopra's SuperS...
313 views • 2 months ago

Cerebral Atrophy with Epilepsy Cured By Dr...
Dr Arpit Chopra's SuperS...
2.9K views • 1 year ago

**Dr Arpit Chopra's SuperS...
2.7K views • 3 years ago**

**Epilepsy with Neurocysticercosis |
Dr Arpit Chopra's SuperS...
37K views • 2 years ago**

**Epilepsy Cured | मिर्च
की बीमारी का परमानेंट इ...
Dr Arpit Chopra's SuperS...
6.3K views • 1 year ago**

**Cerebral Atrophy with Epilepsy Cured.
Dr Arpit Chopra's SuperS...
2.9K views • 1 year ago**

CP. CHRONIC SEIZURES → ON

आरोग्य सुपर स्पेशलिटी मॉडर्न होम्योपैथिक वलीनिक
कम्पलिट * परमानेंट * ईजी * सेफ * फास्ट एण्ड कॉस्ट इफैक्टिव

102, प्रथम मंजिल, कुष्णा टॉवर, खयरेवेल हॉस्पिटल के सामने, जंजीरवाला चौराहा, न्यू पलासिया, इन्दौर (म.प्र.)
फोन : 0731-4977076, मो: 97130-92737, 97130-37737, 79999-78894, 99075-27914

www.homoepathycure.in, www.aarogyahomoeopathyindore.com Email: arpitchopra23@gmail.com

कैंसर, किडनी फेलियर, अस्पताल में गंभीर रूप से भर्ती मरिजों का उपचार, कोमा, शल्य चिकित्सा योग्य रोग, ऑटो इम्यून रोग, जीवनभर दवाई लेने वाले रोगों की रोकथाम एवं 300 प्रकार के असाध्य जटिल रोगों की चिकित्सा।



डॉ. अर्पित चौपडा (जैन)
एम. डी. होम्योपैथी
जटिल, असाध्य एवं
शल्य रोग विशेषज्ञ

आरोग्य सुपर स्पेशलिटी माडर्न होमियोपैथी

कम्पलिट, परमानेन्ट, ईजी, सेफ, फास्ट एण्ड कॉस्ट इफैक्टिव

102, प्रथम मंजिल, कृष्णा टॉवर, क्योरवेल हॉस्पिटल के सामने, जंजीरवाला चौराहा, न्यू पलासिया, इन्दौर म.प्र.

99075 27914 संपर्क : 0731-4977076, 79999 78894

www.homoeopathy cure.in. www.aarogyahomoeopathyindore.com Email : arpitchopra23@gmail.com

bodyScans (Nr Central Lab)
Kothari Diagnostics Pvt Ltd
1st (MZ) Floor, Yashwant plaza

Name Of Patient: MR. AJAY SAROLKAR Age/Sex: 58Y/M
Reporting Date: 29/07/2022 UHID: 1178-22
Ref.By: Dr. ARPIT CHOPRA

MDCT BRAIN Before Treatment

Technique:

A plain MDCT of the brain was performed.

Imaging findings:

There is generalized widening of bilateral cerebral cortical sulci, dilatation of the ventricular system, with widening of sylvian fissures and basal cisterns.

Confluent areas of hypodensities are seen involving bilateral periventricular deep white matter.

Few lacunar infarcts are seen involving the bilateral corona radiata and right caudate nucleus.

No remarkable parenchymal abnormality detected in both the cerebral hemispheres.

KIPIL, M-92, Yashwanth Plaza, Near Central Lab,
Opposite Railway Station, Indore
Branch Office : A-5, Matlam Road, Ash Road,
Beside TVS Durgal, Geeta Bhawan Square, Indore
Call 786-9999-13736
www.bodyscans.in

Before Treatment

Page (2)

Impression: MDCT Brain shows -

- Age related atrophic changes.
- Chronic ischemic changes.
- Old lacunar infarcts in bilateral corona radiata and right caudate nucleus.

- If clinically indicated, an MRI brain is suggested for further evaluation.

Dr. Garima Purohit
MBBS, DMRD, DNB
Consultant Radiologist

AGRAWAL DIAGNOSTIC CENTRE
UJJAIN • INDORE

MRI (1.5 Tesla)
CT Scan (16 Slice)
3D/4D Sonography
Colour Doppler,
ONG-CR & DR
Pathology, ECG & EEG
Digital X-Ray's
Digital Mammography
Echocardiography
EMG, NCV

After Dr Arpit Chopra Jain Modern Homoeopathy

| | | | |
|----------------------|-----------------|---------------|---------------------|
| Patient ID: | 022020923 | Patient Name: | AJAY SAROLKAR 60Y/M |
| Age: | 60 Years | Sex: | M |
| Accession Number: | | Modality: | CT |
| Referring Physician: | DR ARPIT CHOPRA | Study: | HEAD |
| Study Date: | 02-Sep-2023 | | |

NCCT HEAD

Multiple small focal hypodense areas are seen in bilateral periventricular regions, basal ganglia and thalamus, likely representing chronic lacunar infarcts. Ill-defined small focal areas of possible chronic lacunar infarcts are also seen in brainstem.

Remaining overall brain morphology in supratentorial compartment appears normal. No other focal lesion.

There is no fresh hyperdense intracranial hemorrhage. There is no abnormal extra-axial collection or hematoma. There is no midline shift or brain herniation.

Sella and bilateral parasellar regions appear normal. Brainstem and cerebellum otherwise appear grossly normal. Ventricles are intact. No hydrocephalus.

Bones of skull and visualized facial skeleton appear unremarkable. Bilateral orbits and temporal bones appear grossly unremarkable.

DR. SHAIKENDRA KUMAR CHATURVEDI
MD RADIODIAGNOSIS

Date: 02-Sep-2023 17:17:00

UJJAIN : 49, Kailash Mahu Marg, Freeway, Ujjain-480 006
☎ 0734-2518144, 2525534 ☎ 9109-314141
agraval_diagnostic@yahoo.com Pathology: 2519141

देखिए एपिली और एपिलेप्सी का कारण इतना ही है
5:21
होमियोपैथी से

YouTube
Cerebral Atrophy with Epilep...
Epilepsy Cured By Dr. Arpit C...

16:47
2:49

क्या
EPILEPSY
का इलाज
संभव है



न्यूरोलॉजिकल बीमारी

NEUROLOGICAL BRAIN DISEASES Cured

Dr. Arpit Chopra (Jain)

सबसे रस्टोरी

सर्बसे पहले के लिए डॉक्टर होम्योपैथी अपनाये

Cerebral Atrophy is a common feature of many of the diseases that affect the brain

Cerebral atrophy—the loss of nerve cells (neurons) and the connections that help them communicate in the brain's tissues—occurs in many disorders that affect the brain, such as stroke, Alzheimer's, disease, traumatic brain injury, multiple

ALL TYPES OF BRAIN RELATED PROBLEMS CURED BY DR ARPIT CHOPRA JAIN'S M...

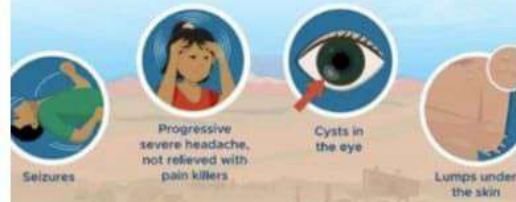Cerebellar Ataxia

- Cerebellar Ataxia- uncoordinated movement due to lesion in the cereb.
- Ataxic gait- unsteady walk

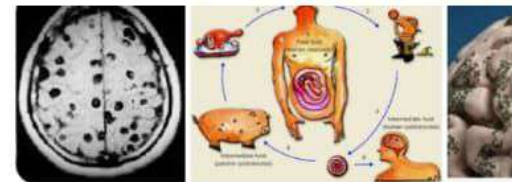
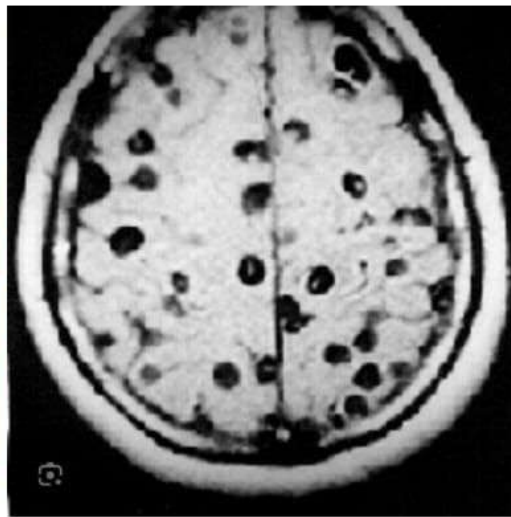
Cerebellar ataxia with Cerebral

SYMPTOMS AND SIGNS

compatible or associated with
NEUROCYSTICERCOSIS



People showing any of these symptoms signs should not receive praziquantel without medical supervision



Neurocysticercosis is a preventable parasitic infection caused by larval cysts (enclosed sacs containing the immature stage of a parasite) of the pork tapeworm (*Taenia solium*). The larval cysts can infect various

City X-ray & Scan Clinic Pvt. Ltd.
SANKI TOWER, New Delhi-110028
E-12, Vasant Park, New Delhi-110014
011-47252000
Website: www.cityxrayandscan.com

MRI BRAIN WITH CONTRAST
PROTOCOLS: Axial T1WSE, T2E-T2W and FLAIR pulse sequences. Sagittal T2E-T2W pulse sequences. DWI & SWI are also performed. Multiphase T1W post-contrast sequences were obtained. Volumes of contrast is 10 ml.

OBSERVATIONS:
There is evidence of a small ring-shaped lesion with T2 hyperintense contents and T1 / T2 / FLAIR hypointense thick rim and a tiny T2 / T1 / FLAIR hypointense eccentric nodule is noted in left frontal region without any significant perilesional edema. It shows significant blooming on SW images. On post contrast T1 images, there is mild diffuse peripheral enhancement. It measures approx. 10.2 x 7.7 x 8.3 mm. Findings are suggestive of an inflammatory granuloma, most likely neurocysticercosis.

IMPRESSION: Peripherally enhancing lesion without any significant perilesional edema in left frontal lobe as described above. Findings are suggestive of an inflammatory granuloma, most likely neurocysticercosis.

Please correlate clinically.

Dr. Anshu Kumar MD (Radiology) Consultant Radiologist
Dr. Anshu Kapoor MD (Radiology) Consultant Radiologist
Dr. Satish Kumar MD (Radiology) Consultant Radiologist
Dr. Rajesh Datta MD (Radiology) Consultant Radiologist

Before Treatment

City X-RAY & SCAN CLINIC PVT. LTD.
SANKI TOWER, New Delhi-110028
E-12, Vasant Park, New Delhi-110014
011-47252000
Website: www.cityxrayandscan.com

MRI BRAIN
PROTOCOLS: Axial T1WSE, T2E-T2W and FLAIR pulse sequences. Sagittal T2E-T2W pulse sequences. DWI & SWI are also performed.

CLINICAL DETAILS: Follow up case of brain cyst.

OBSERVATION:
Calcified cyst with mural nodule seen in left frontal lobe. It measures approx. 5 x 4 mm. No surrounding edema seen.

Rest of the brain parenchyma demonstrates normal morphology & signal intensity patterns. Gray-white matter differentiation is well maintained with normal myelination patterns for age. Ventricular system, cisterns & sulci appear normal. Posterior fossa structures appear normal. Sellar and parasellar regions are unremarkable. No evidence of any focus of restricted diffusion to suggest acute infarct. No evidence of any extra-axial collection / mass lesion or hemorrhage. Normal major intracranial flow voids visualized.

IMPRESSION: Calcified cyst with mural nodule in left frontal lobe without any surrounding edema.

Please correlate clinically.

*** End Of Report ***

Dr. Anshu Kumar MD (Radiology) Consultant Radiologist
Dr. Anshu Kapoor MD (Radiology) Consultant Radiologist
Dr. Satish Kumar MD (Radiology) Consultant Radiologist
Dr. Rajesh Datta MD (Radiology) Consultant Radiologist

After Dr Arpit Chopra Jain Modern Homoeopathy



EPILEPSY CURE NEUROCYSTICER

EPILEPSY CASE TREATMENT DETAIL
मिर्गी की बीमारी का सफल इलाज
सुनि वर्मा
सक्सेस स्टोरी
मॉडर्न होमियोपैथी के द्वारा

Cured | मिर्गी की बीमा...

अरोग्य सुपर स्पेशलिटी
होमियोपैथिक क्लिनिक (कम्प्यूटराड्ड)

Dr Arpit Chopra (Jain)
सर्जरी बचाने के लिए मॉडर्न होमियोपैथी अपनाये
न्यूरोलॉजिकल बीमारी
NEUROLOGICAL BRAIN DISEASES Cured
सक्सेस स्टोरी

कैंसर, किडनी फेलियर, अस्पताल में गंभीर रूप
भर्ती मरिजों का उपचार, कोमा, शल्य चिकित्सा योग
ऑटो इम्यून रोग, जीवनभर दवाई लेने वाले रोगों की रो
300 प्रकार के असाध्य जटिल रोगों की चिकित्सा
आरोग्य सुपर स्पेशलिटी मॉडर्न होमि
कम्पलिट, परमानेंट, ईजी, सेफ, फास्ट एण्ड कॉस्ट इफै
मंजिल, कृष्णा टॉवर, कयोरेवेल हॉस्पिटल के सामने, जंजीरवाला चौराहा,
99075 27914 संपर्क : 0731-4977076, 79999 78894
eopathy.cure.in, www.aarogyahomeopathyindore.com Email : ar

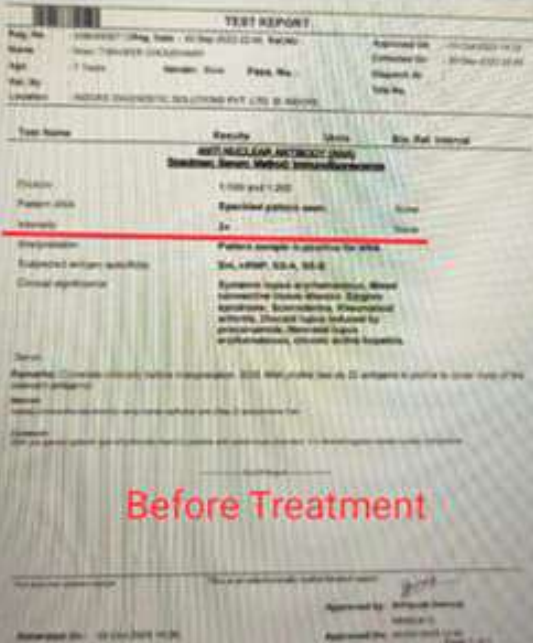
Connective Tissue Diseases

- Common disorders such as Rheumatoid Arthritis (RA), Osteoarthritis (OA) or more rare conditions such as systemic lupus erythematosum (SLE) & Scleroderma
- Commonly referred to as Autoimmune Diseases
- Can be life threatening or merely inconvenient
- Problems cause limitations in mobility and activities of daily living as well as systemic effects that can lead to organ failure and death

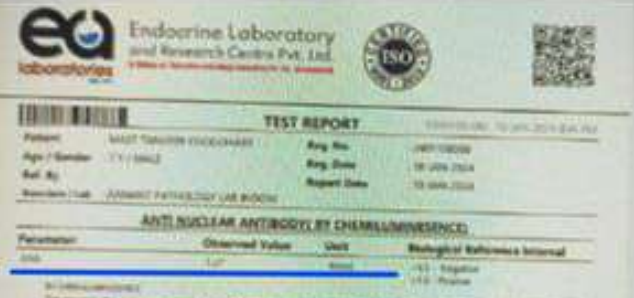


Types of Connective Tissue Diseases

- Lupus
- Rheumatoid arthritis
- Scleroderma
- Sjogren's syndrome
- Dermatomyositis
- Microscopic polyangiitis
- Churg-Strauss syndrome
- Granulomatosis with polyangiitis



Before Treatment



After Dr Arpit Chopra Jain Modern Homoeopathy

el0 cubical rally : eyes
 ? Connective tissue disease
 → ANA : ++ (Aug 22).
 → Unable to walk / talk

डॉ. अर्पित चोपड़ा जैन ने किया रिसर्च एवं प्रमाणित सुपर स्पेशलिटी मॉडर्न होम्योपैथिक चिकित्सा का आविष्कार

कैंसर, किडनी फेलियर, अस्पताल में गंभीर रूप से भर्ती मरिजों का उपचार, कोमा, शल्य चिकित्सा योग्य रोग, ऑटो इम्यून रोग, जीवनभर दवाई लेने वाले रोगों की रोकथाम एवं 300 प्रकार के असाध्य जटिल रोगों की चिकित्सा।

डॉ. अर्पित चौपड़ा (जैन)
 एच. बी. होम्योपैथी
 जटिल, असाध्य एवं
 शल्य रोग विशेषज्ञ

आरोग्य सुपर स्पेशलिटी माईन होमियोपैथी
 कम्पलिट, परमानेंट, ईजी, सेफ, फास्ट एण्ड कॉस्ट इफैक्टिव

102, प्रथम मंजिल, कृष्णा टॉवर, क्योरवेल हॉस्पिटल के सामने, जंजीरवाला चौराहा, न्यू पलासिया, इन्दौर म.प्र.
 99075 27914 संपर्क : 0731-4977076, 79999 78894

EPILEPSY

Symptoms

- Loss of Consciousness
- Anxiety
- Staring
- Weakness
- Muscle Contraction and Jerking

Epilepsy is a Disorder Marked by DISTURBED ELECTRICAL RHYTHMS in the Central Nervous System

EPILEPSY CUR

Before Treatment

After Dr Arpit Chopra Jain Modern Homoeopathy

केसर, किडनी कैल्शियम, अस्थितान में नमीर रूप से चर्बी नरिनों का उपचार, कोषा, राज्य विकिरण योग्य रोग, ओटी इन्फ्लू रोग, नीचतर बवाई लेने वाले रोगों की चेकअप एवं 300 प्रकार के असाध्य जटिल रोगों की चिकित्सा।

आरोग्य सुपर स्पेशलिटी मॉडर्न होमियोपैथी

कम्प्लिक्स, परमाणु, ईन्टी, सेल, फास्फ रूपा का उपयोग

112, बस स्टैंड, दुधवा रोड, अमरकोट इलाहाबाद के समीप, पंचसाला रोड, नु. पंचसाला, अमरकोट, U.P.

Brain Granuloma: Cure Without Surgery In 2 Months

Calcified Granuloma & Brain Tumour cancerous & non cancerous cured & responded by Dr Arpit...

• केसर • किडनी कैल्शियम • अस्थितान में नमीर रूप से चर्बी नरिनों का उपचार • कोषा • राज्य विकिरण योग्य रोग • ओटी इन्फ्लू रोग • नीचतर बवाई लेने वाले रोगों की चेकअप एवं 300 प्रकार के असाध्य जटिल रोगों की चिकित्सा

आरोग्य

clo Epilepsy :: 2009

on R

Last episode - Oct 2022

Last for - 5-7 mins

Vertigo ⊕

Nausea

LMP - 30/5/23

6 days flow

EEG - Abnormal

R.D. GARDI MEDICAL COLLEGE, DEPT. OF NEUROLOGY, LJAIAN (MP)

PATIENT INFORMATION

NOTES

Before Treatment

Report of Electroencephalogram

Under record: Elec frequency 10 per sec. well synchronous alpha waves.

Discrete alpha rhythm, theta 5 sleep wave on record.

Short bursts of generalized sharp & slow wave are recorded (page no - 25) at the later part of the graph.

Imp - Compared with the previous report of 25.8.19 EEG shows marked abnormality and evidence of Epileptiform activity.

Dr. Arpit Vyas, MD, DNB (Neuro) Consultant, Neurologist

AGRAWAL DIAGNOSTIC CENTRE

Pt Name: MR ANSHU NAGORI

Ref by Dr: ANIL VYAS

ELECTROENCEPHALOGRAM (EEG) REPORT

EEG PROTOCOL:

- Sleep EEG done under 10-20 international system of electrode placement. Bilateral transverse, longitudinal & monopolar montages were used.
- Photo stimulation, sleep were used as activation procedure.

EEG REPORT:

- Sleep EEG record showing background activity of 2-3Hz (80-85 micro volts) delta activity intermittent 4-6 (4-40-60 micro volts) theta activity with left to right asymmetry.
- Photo stimulation were unremarkable.

IMPRESSION:

NORMAL EEG RECORD

After Dr Arpit Chopra Jain Modern Homoeopathy

Seizure :: Childhood

episode - 2021

last for = 5 mins

Rx (Calcium therapy)

fever (infection to B in child)

+ मीरा

सुवेदी आयुर्वेदिक

ANAL EEG REPORT

EEG RECORDING SHOWS:

- Background with alpha rhythm which is 8-11 Hz in Sleeps and 20-40 µV in awake state, posterior dominant rhythm is very regular, fast delta activity seen in frontal lobe region and slow theta rhythm seen in temporal region.
- Activation Procedure:** Hyperventilation and Photo Stimulation could not continue any marked abnormality.
- Remarks:** For finding and evolution artifact seen in following.
- There are Generalized sleep and slow wave discharge seen in the marking.

Impression: There is electro-physiologic evidence of suggestive of seizure disorder.

Before Treatment

DIAGNOSTIC CENTRE

Pt Name: MR ANSHU NAGORI

Ref by Dr: ANIL VYAS

ELECTROENCEPHALOGRAM (EEG) REPORT

EEG PROTOCOL:

- Sleep EEG done under 10-20 international system of electrode placement. Bilateral transverse, longitudinal & monopolar montages were used.
- Photo stimulation, sleep were used as activation procedure.

EEG REPORT:

- Sleep EEG record showing background activity of 2-3Hz (80-85 micro volts) delta activity intermittent 4-6 (4-40-60 micro volts) theta activity with left to right asymmetry.
- Photo stimulation were unremarkable.

IMPRESSION:

NORMAL EEG RECORD

After Dr Arpit Chopra Jain Modern Homoeopathy

Progressive supranuclear palsy (PSP) is a rare, progressive neurological disorder that damages nerve cells in specific areas of the brain, particularly those that control movement, balance, vision, speech, and swallowing. It is a form of atypical parkinsonism caused by the accumulation of a protein called tau. There is currently no cure for PSP, and treatment focuses on managing symptoms to maintain quality of life.

PROGRESSIVE SUPRANUCLEAR PALSY

Clinical Hallmarks

- Prominent axial rigidity and retrocollar posture
- Worried faces
- Slow vertical saccades
- Early stiffness and falls
- Supranuclear vertical gaze palsy

PATHOLOGICAL HALLMARKS

- Hummingbird sign
- TAU PROTEIN Globulose neurofibrillary tangles

Progressive supranuclear palsy -... [Visit >](#)

Dr. Agnihotri's Path Lab & Diagnostic Center

Reg No. CLAB0002007

Sample Collected on: 18-Jun-2025 12:33 PM
 Sample Received on: 18-Jun-2025 12:42 PM
 Report Released on: 18-Jun-2025 4:57 PM

ANA PROFILE

| Investigation | Result | Unit | Dis. Ref. Range |
|---------------|--------|------------|--------------------------------------------------------------------------------------------------------------------|
| ANA / Sm | 0.0 | INDEX/VALU | 0 - 5 NEGATIVE 6 - 10 BORDERLINE 11 - 25 POSITIVE (+) 26 - 50 POSITIVE (++) > 50 STRONG POSITIVE (+++) |
| Sm D1 | 0.0 | INDEX/VALU | 0 - 5 NEGATIVE 6 - 10 BORDERLINE 11 - 25 POSITIVE (+) 26 - 50 POSITIVE (++) > 50 STRONG POSITIVE (+++) |
| SS-A / RO 60 | 2.0 | INDEX/VALU | 0 - 5 NEGATIVE 6 - 10 BORDERLINE 11 - 25 POSITIVE (+) 26 - 50 POSITIVE (++) > 50 STRONG POSITIVE (+++) |
| SS-A / RO 52 | 7.8 | INDEX/VALU | 0 - 5 NEGATIVE 6 - 10 BORDERLINE 11 - 25 POSITIVE (+) 26 - 50 POSITIVE (++) > 50 STRONG POSITIVE (+++) |
| SS-B | 2.0 | INDEX/VALU | 0 - 5 NEGATIVE 6 - 10 BORDERLINE 11 - 25 POSITIVE (+) 26 - 50 POSITIVE (++) > 50 STRONG POSITIVE (+++) |
| SS-70 | 1.0 | INDEX/VALU | 0 - 5 NEGATIVE 6 - 10 BORDERLINE 11 - 25 POSITIVE (+) 26 - 50 POSITIVE (++) > 50 STRONG POSITIVE (+++) |

Before Treatment

Path Lab & Diagnostic Center

Sample Collected on: 18-Jun-2025 12:33 PM
 Sample Received on: 18-Jun-2025 12:42 PM
 Report Released on: 18-Jun-2025 12:32 PM

ANA PROFILE

| Investigation | Result | Unit | Dis. Ref. Range |
|---------------|--------|------------|--------------------------------------------------------------------------------------------------------------------|
| ANA / Sm | 0.0 | INDEX/VALU | 0 - 5 NEGATIVE 6 - 10 BORDERLINE 11 - 25 POSITIVE (+) 26 - 50 POSITIVE (++) > 50 STRONG POSITIVE (+++) |
| Sm D1 | 0.0 | INDEX/VALU | 0 - 5 NEGATIVE 6 - 10 BORDERLINE 11 - 25 POSITIVE (+) 26 - 50 POSITIVE (++) > 50 STRONG POSITIVE (+++) |
| SS-A / RO 60 | 0.0 | INDEX/VALU | 0 - 5 NEGATIVE 6 - 10 BORDERLINE 11 - 25 POSITIVE (+) 26 - 50 POSITIVE (++) > 50 STRONG POSITIVE (+++) |
| SS-A / RO 52 | 0.0 | INDEX/VALU | 0 - 5 NEGATIVE 6 - 10 BORDERLINE 11 - 25 POSITIVE (+) 26 - 50 POSITIVE (++) > 50 STRONG POSITIVE (+++) |
| SS-B | 0.0 | INDEX/VALU | 0 - 5 NEGATIVE 6 - 10 BORDERLINE 11 - 25 POSITIVE (+) 26 - 50 POSITIVE (++) > 50 STRONG POSITIVE (+++) |
| SS-70 | 2.0 | INDEX/VALU | 0 - 5 NEGATIVE 6 - 10 BORDERLINE 11 - 25 POSITIVE (+) 26 - 50 POSITIVE (++) > 50 STRONG POSITIVE (+++) |

During Dr Arpit Chopra Jain Modern Homeopathy Treatment

PROGRESSIVE SUPRANUCLEAR PALSIA on Rx (H)

- Imbalance while walking
- Dysarthria
- Sluggish speech (+) Slurring (-)
- H/o urinary incontinence

31:25

न्यूरोलॉजिकल बीमारी NEUROLOGICAL BRAIN DI...

Common Neurological Disorders

- Migraines
- Parkinson's disease
- Brain Tumors
- Epilepsy
- Stroke
- Alzheimer's disease
- Phenytoin


जाराय सुपर स्पेशलिटी भाइने होमोपैथीक क्लिनिक
 AARON'S SUPER SPECIALITY MODERN-HOMOEOPATHIC CLINIC



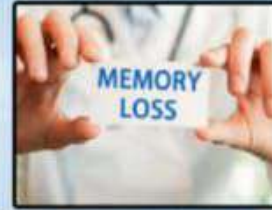AAROGYA SUPER SPECIALITY MODERN HOMOEOPATHIC CLINIC



DR ARPIT CHOPRA JAIN
(MD HOMOEOPATHY CRITICAL & SURGICAL DISEASE SPECIALIST)



RESPONDED MEMORY LOSS PATIENT
FROM UJJAIN, MADHYA PRADESH



97130-37737, +91 80451-32033. Websites - www.homoeopathycure.in, www.aarogyahomoeopati

TYPES OF DEMENTIA

Dementia is an umbrella term for loss of memory and other thinking abilities severe enough to interfere with daily life.

- Alzheimer's
- Vascular
- Lewy Body
- Frontotemporal
- Mixed dementia (Alzheimer's + vascular)

Dementia is a progressive decline in memory and cognitive functions, like thinking and reasoning, severe enough to interfere with daily life. While memory loss is a common symptom, dementia also involves other difficulties, including trouble with language, visual perception, problem-solving, and personality changes. It is not a normal part of aging, but rather a syndrome caused by various underlying diseases.

आरोग्य सुपर स्पेशलिटी मॉडर्न होम्योपैथिक क्लिनिक

AAROGYA SUPER SPECIALITY MODERN HOMOEOPATHIC CLINIC

कैंसर, किडनी फेलियर, अस्पताल में गभीर रूप से भर्ती मरीज का उपचार, कोमा, शल्य चिकित्सा योग्य ऑटोइम्यून रोग, अप्लास्टिक ऐनीमिया, मस्कलर डिस्टॉफी, जीवन भर दवा लेने वाले रोगों की रोकथाम व 300 प्रकार के असाध्य जटिल रोगों की चिकित्सा

हमारी कोई अन्य शाखा नहीं है | प्रौढ कौम से सावधान रहें | Online Consultation Available

+91 99075-27914, +91 97130-92737, +91 97130-37737, +91 93404-95872, +91 79995-78894

101, 102, X13, 104, KRISHNA TOWER, JALDEHRNLA SQUARE, INFRONT OF CORNELL HOSPITAL ROAD, NEW PALASIA, INDORE - 452033 (M.P.)

ALL TYPES OF BRAIN RELATED PROBLEMS CURED BY DR ARPIT CHOPRA JAIN'S MODERN

31:25

न्यूरोलॉजिकल बीमारी
NEUROLOGICAL BRAIN DI...

Common Neurological Disorders

- Paralysis
- Alzheimer's disease
- Epilepsy
- Stroke
- Migraines
- Parkinson's disease
- Brain tumour



Cerebellar ataxia wit...
YouTube



Cerebral Atrophy...
YouTube



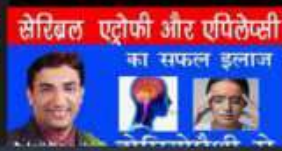Cerebral Palsy CP...
YouTube



Cerebral Atrophy...
YouTube

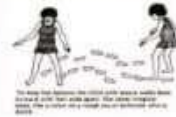

Cerebral Atrophy...
YouTube

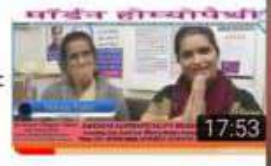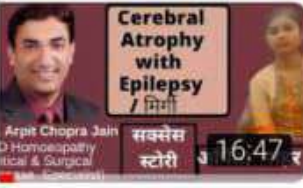


Cerebellar Ataxia

- Cerebellar Ataxia- uncoordinated movement due to lesion in the cerebellum
- Ataxic gait- unsteady walk



Cerebellar ataxia with Cerebral Atrophy patient responded by Dr Arpit Chopra Jain Modern Homoeopathy



CENTRAL HELPLINE NO. 000 4000 8000 / 022 3302 0302

RB DIAGNOSTIC

ACC. NO. / RPT NO. / PAT ID : PMS798899

PATIENT : Mr. BUNOO KUNAR BUNTA

AGE/SEX : 61 Y / Male

REF. BY : Dr. ADITYA DAKSHIN - (MEDICINE)

Private Sample / Blood (SPTA/CLIST)

Department of Serology

| Test | Result | Bio. Ref. Interval | Units | Methodology |
|-----------------------------|--------|------------------------|-------|--------------------|
| CDP | 58.3 | 0 - 1 | mg/L | Immunoturbidimetry |
| ANA (Anti Nuclear Antibody) | 0.20 | Negative - <1.0 | Index | IFA |
| | | Sensitivity: 1.0 - 1.0 | | |
| | | Specificity: 1.0 - 1.0 | | |

Dr. Arpit Chopra Jain
MD (Medicine)
Consultant Homoeopath

Dr. Shantanu Patil Bhatnagar
MD (Medicine)
Consultant Homoeopath

During Dr. Arpit Chopra Jain Modern Homoeopathy

TEST REPORT

ANA by IFA

ANA (Anti Nuclear Antibody) Positive

Nuclear Pattern: NUCLEAR HOMOGENOUS

Cytoplasmic Pattern: None

Mitotic Pattern: None

Specificity Data: AC-1

Intensity / Grade: 3+

Primary Title: 1:100

Antibodies Against: dsDNA, nucleosomes, Histones

Suggested Clinical Correlations:

Found in patients with SLE, chronic atrophic hepatitis or Juvenile idiopathic arthritis. If SLE is clinically suspected, it is recommended to perform a follow-up test for anti-dsDNA antibodies, alone or in combination with dsDNA/histone complexes (nucleosomes) (specimen); anti-dsDNA antibodies are included in the classification criteria for SLE.

Before treatment

healthy vs **cerebral atrophy**

widening of cortical sulci

enlargement of ventricles

thinning of cortex

shrinking of hippocampus

The Shrinking Brain:

Visit >

ALL TYPES OF BRAIN RELATED PROBLEMS CURED BY DR ARPIT CHOPRA JAIN'S MEDICINE 31:25

न्यूरोलॉजिकल बीमारी NEUROLOGICAL BRAIN DI...

Common Neurological Disorders

- Paralysis
- Alzheimer's disease
- Epilepsy
- Stroke
- Migraines
- Parkinson's disease
- Brain tumour

Size 35x38 Inch

आरोग्य (Aarogya)

DR. ARPIT CHOPRA JAIN

आरोग्य सुपर स्पेशलिटी मॉडर्न होम्योपैथिक क्लिनिक

AAROGYA SUPER SPECIALITY MODERN HOMOEOPATHIC CLINIC

कैंसर, किडनी फेलियर, अस्पताल में गंभीर रूप से भर्ती मरीज का उपचार, कोमा, शल्य चिकित्सा योग्य ऑटोइम्यून रोग, अप्लास्टिक ऐनीमिया, मस्कलर डिस्टॉफी, जीवन भर दवा लेने वाले रोगों की रोकथाम व 300 प्रकार के असाध्य जटिल रोगों की चिकित्सा

इम्युनिटी कोर्ट अन्य खाद्य नहीं है | प्रौढ कौन से हाथपाय नहीं | Online Consultation Available




0221-4070705 | +91 97130-57737, +91 80451-82081

+91 90075-27934, +91 97130-92737, +91 97130-57737, +91 93404-01872, +91 79999-78994

101, 102, 103, 104, KALSHAN TRUST, JAIN-EPHRAJA COLONY, NEARBY OF GARDEN HOSPITAL ROAD, NEW PILSUDA, INDIAN - 401101 (M.P.)

आरोग्य सुपर स्पेशलिटी मॉडर्न होम्योपैथीक क्लिनिक

**ब्रेन ट्यूबरकुलोसिस
BRAIN TUBERCULOSIS**

DR. ARPIT CHOPRA JAIN
MD HOMOEOPATHY & CRITICAL & SURGICAL DISEASE SPECIALIST

ब्रेन ट्यूबी, या ट्यूबरकुलस मॉनिंगोटोस मस्तिष्क और रीढ़ की हड्डी के अणुस्तर की परतों (मेनिन्जेस) को प्रभावित करने वाला एक जीवित प्रक्रम है, जो माइकोबैक्टीरियम ट्यूबरकुलोसिस बैक्टीरिया के कारण होता है।

RESPONDED BRAIN TUBERCULOSIS PATIENT FROM MHOW, MADHYA PRADESH

ADDRESS: 101, 102, 103, 104, KRISHNA TOWER, JAMJEERWALA SQUARE, IN FRONT OF CUREWELL HOSPITAL ROAD, NEW PALASIA, INDORE, MADHYA PRADESH 452001

2:25

Title
तेज़ सुधार सिर्फ़ 10 दिनों में Neurological Impairment due to Brain TB responded by DrArpitChopraJain

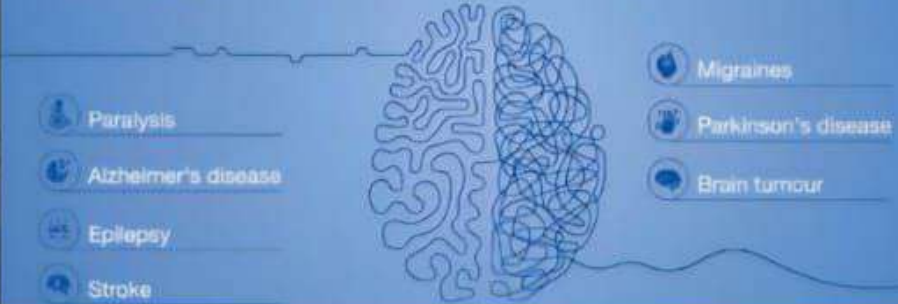


ALL TYPES OF BRAIN RELATED PROBLEMS CURED BY DR.ARPIT CHOPRA JAIN'S MODERN

31:25

**न्यूरोलॉजिकल बीमारी
NEUROLOGICAL BRAIN DI...**

Common Neurological Disorders



- Paralysis
- Aizheimer's disease
- Epilepsy
- Stroke
- Migraines
- Parkinson's disease
- Brain tumour

आरोग्य सुपर स्पेशलिटी मॉडर्न होम्योपैथीक क्लिनिक
AAROGYA SUPER SPECIALITY MODERN HOMOEOPATHIC CLINIC

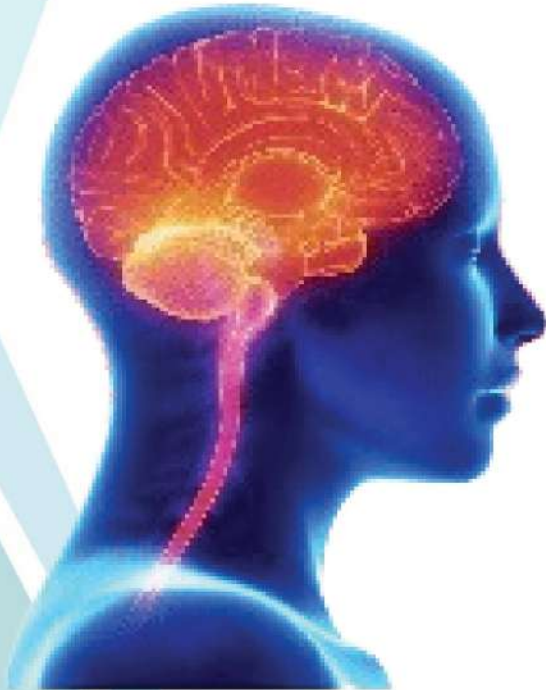ब्रेन, किडनी डेटिज, अणुस्तर से लड़ने का ही सही पान है। अणुस्तर, डीएनए, बायोलॉजिकल प्रोसेस, आणविक इंजीनियरिंग, जीन एंड डीएनए एंड सेलुलर-रिसेप्टर एंड 300 प्रोटीन के अणुस्तर पर ही की गई है।

0731-4877076 | 01 79899-78884, 01 93130-92727, 01 93404-95872, 01 93076-27914 | 01 93130-37727, 01 80461-50223, 01 932933882

Address: 101, 102, 103, 104, Krishna Tower, Jamjeerwala Square, in front of Curewell Hospital Road, New Palasia, Indore, Madhya Pradesh 452001

Email: arpit Chopra23@gmail.com

DR. ARPIT CHOPRA JAIN
MD HOMOEOPATHY & CRITICAL & SURGICAL DISEASE SPECIALIST



BRAIN TUMOR

LIFETIME MEDICINE

EPILEPSY मिरगी

पागल डिसेबल कमजोर दिमाग ऊपरी हवा कम आइंक्यु

WEAK OR DISABLE

NEUROLOGICAL DISORDER NO PERMANENT CURE

MYTH & MISCONCEPTION

COMA

Statistics on mental illness
 300 million
 0.06%

BRAIN HEMORRHAGE

BRAIN STROKE

PARKINSON'S

Om Prakash Patidar Dhamnod, M.P.

BRAIN STROKE

Shruti Chawda Indore, (M.P)

MENINGIOMA

Manoj Tiwari

Fahr Disease

Dwipati Gaur

CAVERNOMA

Ashya Anand Indore, M.P

GBM Glioblastoma

HEL, KISHU KUMAR, INDORE

MUSCULAR DYSTROPHY

Pawan Jain Indore, M.P

COMA

Arpita Nahar Indore, M.P

EPILEPSY

Shyama Bai Rathore Indore, M.P

Brain Tumor

Shruti Verma Gwalior, M.P

EPILEPSY



Service Project Infrastructure: Making Medical Care Accessible to All

"Medical facilities should be accessible to the common man in every way." Dr. Arpit Chopra Jain

To make his groundbreaking medical invention available to the general public, Professor Dr. Arpit Chopra Jain has established the Aarogya Super Speciality - Modern Homoeopathy Clinic, equipped with state-of-the-art facilities, at Janjirwala intersection in the heart of Indore city. At this clinic, patients have access to comprehensive consultation, diagnosis, and treatment for various diseases, all under one roof.

In addition, a dedicated consultation room for online patients has been set up to offer virtual consultations. Medicines are delivered through courier services, ensuring that even the most serious conditions can be treated from the comfort of one's home. Dr. Arpit Chopra Jain's initiative ensures that high-quality healthcare is not just limited to in-person visits but is also accessible to those in distant locations.





Dr. Arpit Chopra Jain: A Commitment to Service and Responsibility

Dr. Arpit Chopra Jain, raised in a family of doctors, embodies the true essence of a dedicated medical professional. With a deep sense of responsibility toward human welfare, he has revolutionized healthcare through his groundbreaking invention of Super Speciality Modern Homoeopathy treatment. His work has provided a new direction in treating complex diseases, ensuring that even those who once felt hopeless have found relief.

campaign to combat sickle cell anemia, Dr. Arpit Chopra Jain is also working tirelessly in tribal areas. His efforts contribute significantly to the permanent and successful treatment of this genetic disorder, further reflecting his unwavering commitment to the welfare of humanity.



Dr. Arpit Chopra Jain also organizes medical camps aimed at diagnosing complex diseases, providing free consultations to those in need. His sense of duty was especially evident during the devastating COVID-19 pandemic, where he took extraordinary measures to help his community. Understanding the gravity of the situation, he distributed free Corona prevention medicines to approximately 2,25,000 people, including Corona Warriors, potentially saving many lives.





Dr. Arpit Chopra Jain exemplifies what it means to be a physician who balances medical practice with social responsibility, continuing to make a profound impact on both individual lives and society as a whole.



Recognizing the significance of his role, Dr. Arpit Chopra Jain extends his responsibilities beyond medical practice. He considers it his moral and national duty to contribute to various social service activities. Along with treating complicated medical conditions, Dr. Arpit Chopra Jain is committed to shaping the future of homoeopathy. He actively mentors and educates new students entering the field, helping them gain the knowledge necessary to advance in medical science.





Samman Awards: A Tribute to Responsibility and Service

"Respect received from society increases responsibility." Dr. Arpit Chopra Jain

Dr. Arpit Chopra Jain believes that when one contributes responsibly and at the right time, society offers its respect. However, with that respect comes an even greater sense of responsibility.

Dr. Arpit Chopra Jain, through his groundbreaking invention of the Arogya Super Speciality Modern Homoeopathy medical system and his numerous social contributions, has garnered widespread recognition. His dedication to improving the health and well-being of others has not gone unnoticed. He has been honored by many prominent ministers, intellectuals, and senior artists across various dignified platforms. These awards have been bestowed upon him by social, national, and international institutions, further acknowledging his remarkable contributions to the field of medicine and humanity.

This recognition only fuels Dr. Arpit Chopra Jain's determination to continue serving society with even greater dedication and responsibility.

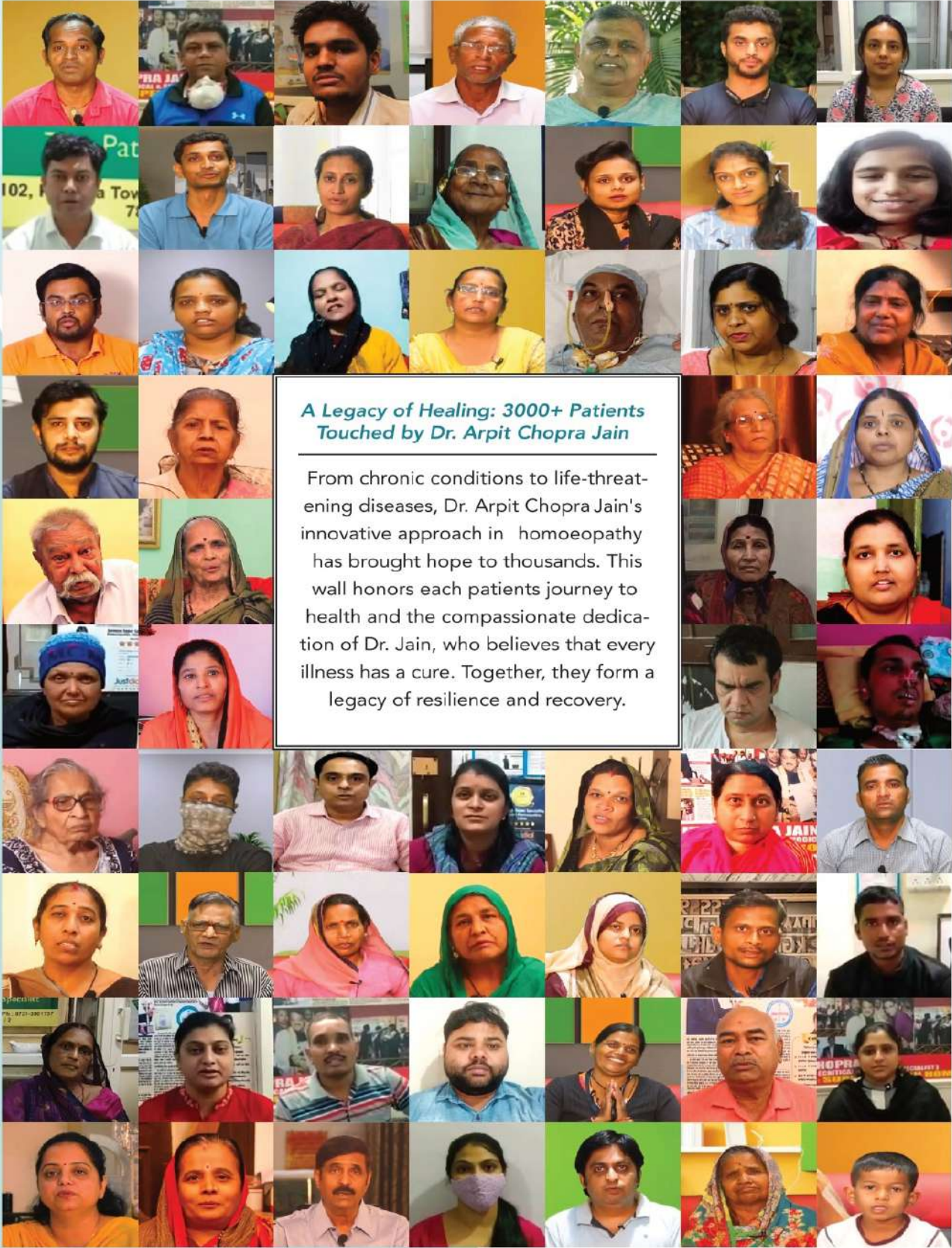






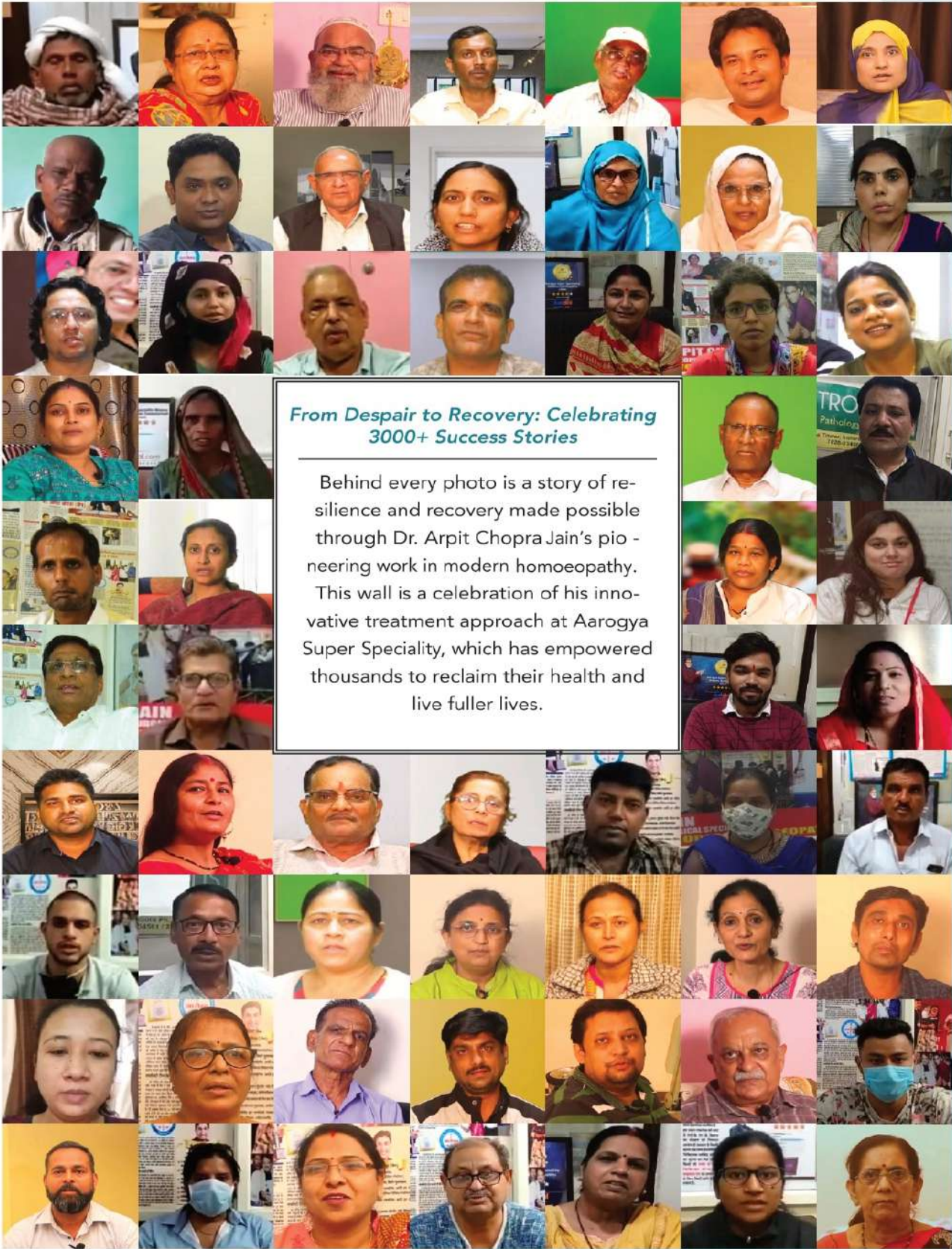




A Legacy of Healing: 3000+ Patients Touched by Dr. Arpit Chopra Jain

From chronic conditions to life-threatening diseases, Dr. Arpit Chopra Jain's innovative approach in homoeopathy has brought hope to thousands. This wall honors each patients journey to health and the compassionate dedication of Dr. Jain, who believes that every illness has a cure. Together, they form a legacy of resilience and recovery.



From Despair to Recovery: Celebrating 3000+ Success Stories

Behind every photo is a story of resilience and recovery made possible through Dr. Arpit Chopra Jain's pioneering work in modern homoeopathy. This wall is a celebration of his innovative treatment approach at Aarogya Super Speciality, which has empowered thousands to reclaim their health and live fuller lives.



Thank
You!



Possible solutions to complex, incurable and impossible diseases. Harmless, quick, economical and permanent treatment system, Homoeopathy of the future, Thank you for giving your valuable time to Super Speciality Modern Homoeopathy treatment system.


May you always live a happy life by staying physically,
mentally and socially healthy and fulfill the WHO standards


This is my wish, This is my effort...


Aarogya Super Speciality Modern Homoeopathy

101-104, First Floor, Krishna Tower, Opposite Curewell Hospital
New Palasia, INDORE (M.P.)

ONLINE CONSULTATION ALSO AVAILABLE

 @ 99075-27914, 79999-78894
@ 97130-92737, 97130-37737

 aarogya101

 [instagram.com/aarogyahomeopathy](https://www.instagram.com/aarogyahomeopathy)

 www.aarogyahomeopathyindore.com

www.aarogyahomeopathyindore.com
www.homoeopathycure.in
besthomoeopapathdoctorind.com

email : arpitchopra23@gmail.com, aarogyamodernhomeopathy@gmail.com

You Tube Link  - [drarpitchopramodernhomeopathic](https://www.youtube.com/channel/UCdrarpitchopramodernhomeopathic)